

Series Editors: Angelo P. Giardino, MD, PhD  
Patrick S. Pasquariello, Jr., MD

## A 10-Month-Old Infant with Progressive Abdominal Distension

Hande Kaymakcalan, MD  
Sudha Rao, MD

### CASE PRESENTATION

#### History

A 10-month-old previously healthy girl was brought to the pediatric emergency department with a 6-week history of progressive abdominal distension noted by her grandmother. The grandmother stated that the infant was otherwise asymptomatic and was gaining weight appropriately. Past medical history was unremarkable. She was a full-term baby, delivered vaginally without any complications. The grandmother could not recall the infant's birth weight and length. The infant was fed formula alone for 4 months and was then given age-appropriate infant cereal and table food. There were no feeding problems over the last 6 weeks. The infant received routine immunizations at the 2-, 4-, and 6-month well-child visits, and the physician did not note any unusual findings on those visits. The family history was noncontributory. There was no foreign travel. Two months before presentation, the infant had visited her father in Texas and had contact with a pet dog.

#### Key Point

Enlargement of the abdomen can result from diminished tone of the wall musculature, increased content (fluid, gas, or solid), an abdominal organ which diffusely enlarges, or an isolated mass.

#### Physical Examination

The infant was well developed, well nourished, active, alert and happy. The facies appeared unremarkable, with a normal hairline and without coarse or dysmorphic features. Review of systems was not contributory. Vital signs included a rectal temperature of 100.4°F (38°C), heart rate of 138 bpm (50th percentile for age), respiratory rate of 20 breaths/min, and blood

pressure of 96/69 mm Hg (75th percentile for age). The weight was at the 25th percentile, the height at the 50th percentile, and the head circumference at the 25th percentile.

The infant was not in any acute distress and was quite comfortable during the examination. There were no distended neck veins. Results of the cardiovascular examination were normal. She was breathing comfortably without retractions. The lungs were clear to auscultation, and there was good air entry bilaterally. The abdomen was grossly distended, with a maximum girth of 50 cm. Dilated superficial veins were observed over the abdominal wall without an obvious caput medusa. The liver was palpable 3 cm below the right costal margin in the right mid-clavicular line, liver span on percussion was 15 × 10 cm, and the liver surface was smooth. No bruit was heard on auscultation of the liver. The spleen was not enlarged. Rectal examination was normal. There was no jaundice, skin rash, or peripheral edema. There was no lymphadenopathy. The skin was normal without evidence of any hemangiomas.

#### Discussion

In the initial evaluation, the patient's history revealed a positive contact with a dog. Both *Toxocara canis*

---

*At the time of submission, Dr. Kaymakcalan was a third-year Pediatric Resident in the Department of Pediatrics, John H. Stroger, Jr. Hospital of Cook County, Chicago, IL. Dr. Kaymakcalan currently is in private practice in Istanbul, Turkey. Dr. Rao is the Chairman of the Division of Pediatric Hematology and Oncology and Residency Program Director, John H. Stroger, Jr. Hospital of Cook County. Dr. Giardino is the Vice President of Clinical Affairs and the Associate Chair of Pediatrics, St. Christopher's Hospital for Children, Philadelphia, PA; and a member of the Hospital Physician editorial board. Dr. Pasquariello is the Director of the Diagnostic Center, Division of General Pediatrics, Department of Pediatrics, Children's Hospital of Philadelphia, Philadelphia, PA.*

(continued on page 23)

(from page 20)

**Table 1.** Complete Blood Count and Chemistry Panel for the Case Patient

Study	Results	Normal Range
<b>Complete blood count</b>		
Hemoglobin	14.1 g/dL	10.5–12.0 g/dL
Hematocrit	43.1%	33%–36%
Leukocytes	$13.8 \times 10^3/\text{mm}^3$	$6\text{--}17 \times 10^3/\text{mm}^3$
Platelets	$436 \times 10^3/\text{mm}^3$	$150\text{--}350 \times 10^3/\text{mm}^3$
Neutrophils	10%	10%–30%
Lymphocytes	81%	57%–61%
Basophils	8%	1%–10%
Eosinophils	4%	0–3%
<b>Chemistry panel</b>		
Sodium	140 mEq/L	135–145 mEq/L
Potassium	3.7 mEq/L	3.5–5.5 mEq/L
Chloride	115 mEq/L	9–111 mEq/L
Carbon dioxide	13 mEq/L	20–25 mEq/L
Urea nitrogen	7 mg/dL	7–22 mg/dL
Creatinine	0.3 mg/dL	0.2–0.4 mg/dL
Calcium (total)	7.8 mg/dL	8–10.5 mg/dL
Phosphorus	4.8 mg/dL	3.2–6.3 mg/dL
Magnesium	1.9 mEq/L	1.3–2.0 mEq/L
Albumin	3.9 g/dL	3.9–5.0 g/dL
Bilirubin (total)	0.3 mg/dL	< 1.0 mg/dL
GGT	229 U/L	5–35 U/L
AST	113 U/L	20–65 U/L
ALT	51 U/L	< 54 U/L
Cholesterol (total)	139 mg/dL	< 170 mg/dL
LDH	477 U/L	150–360 U/L
Alkaline phosphatase	214 U/L	150–420 U/L

ALT = alanine aminotransferase; AST = aspartate aminotransferase; GGT =  $\gamma$ -glutamyl transferase; LDH = lactate dehydrogenase.

and *Echinococcus granulosus* can cause hepatomegaly, although the latter is rare. However, an infectious etiology for the hepatomegaly appeared unlikely with the child's normal appetite, normal activity, and absence of febrile episodes. The normal hairline and facial features, together with a thriving child, did not support a metabolic etiology. The size of the liver, significant abdominal distension, and the prominent veins over the abdominal wall pointed to an enlarged liver with or without a mass within the liver.

**Table 2.** Tumor Marker Panel for the Case Patient

Tumor Marker	Results	Normal Range
Total serum $\beta$ HCG	< 2.00 mIU/mL	0–10 mIU/mL
AFP	17.20 ng/mL	0–8.80 ng/mL
CA-125	12.40 U/mL	0–31.30 U/mL

AFP =  $\alpha$ -fetoprotein; CA = cancer antigen; HCG = human chorionic gonadotropin.

### Laboratory Studies

Because an infectious etiology appeared unlikely in this patient, metabolic and neoplastic etiologies were considered for the differential diagnosis in this patient. Initial investigations on day 1 included a complete blood count and a complete metabolic panel (Table 1). The hemoglobin and hematocrit were slightly higher than expected for the patient's age. In the absence of dehydration, a hepatic tumor causing erythrocytosis was now under consideration. Elevated aspartate aminotransferase,  $\gamma$ -glutamyl transferase, and lactate dehydrogenase suggested hepatic involvement; however, the normal total bilirubin and normal alkaline phosphatase levels helped exclude an obstructive pathology in the liver. The low calcium level and the borderline neutropenia appeared clinically insignificant.

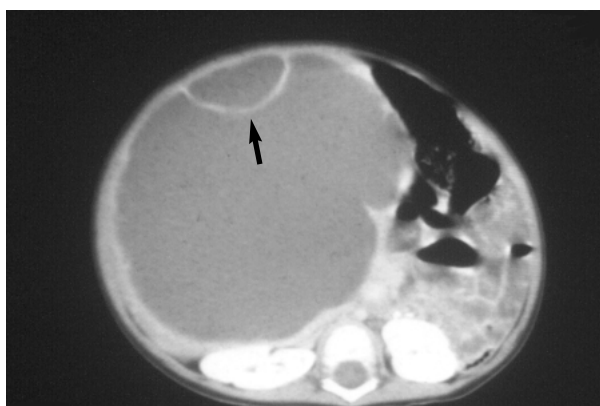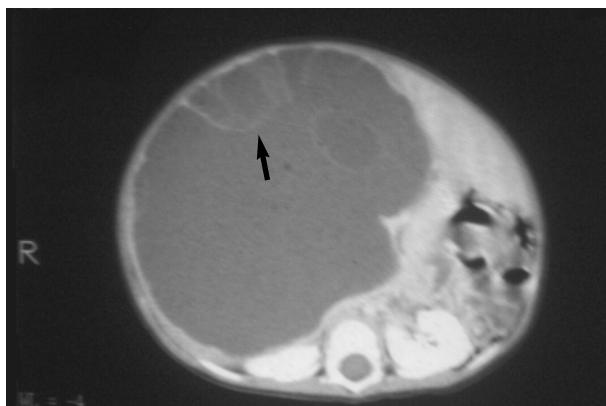
The tumor markers subsequently were requested on day 2 (Table 2). The  $\alpha$ -fetoprotein was only mildly elevated (generally, it is much higher for hepatic tumors) and the  $\beta$ HCG as well as the CA-125 were within normal limits.

### Key Point

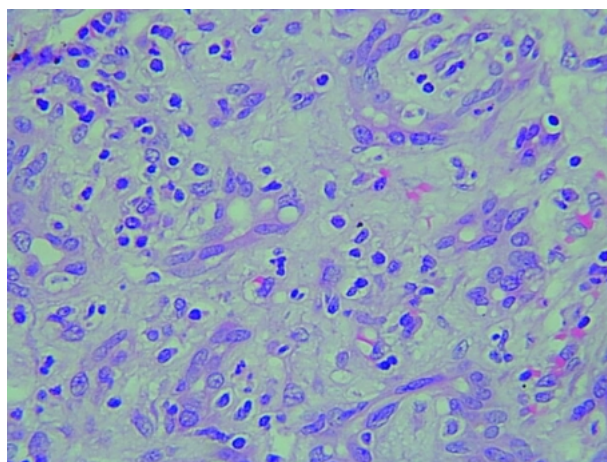
Most children with benign or malignant liver masses present with a palpable mass on physical examination. Other presenting manifestations include pain, anorexia, jaundice, paraneoplastic syndromes (erythrocytosis, thrombocytosis, hypercholesterolemia, hypoglycemia, and hypocalcemia), hemorrhage, congestive heart failure, or renal failure. Although it is often obvious that these children have an abdominal mass without imaging, the origin of the mass is not always clear.

### Imaging Studies

Abdominal radiographs of the infant were ordered in the pediatric emergency department and demonstrated hepatomegaly and dilated bowel loops. Based on these results, computed tomography (CT) scan was ordered to rule out a mass. CT scan of the infant's



**Figure 1.** A computed tomography scan demonstrates multiple septated cystic lesions (arrows) in right lobe of the liver of the case patient. The fluid in the large cysts appear to be more dense than clear. The normal liver tissue has been pushed to the edges by the huge internal cystic mass. Both images demonstrate the bowel loops pushed to the left side of the abdomen by the large liver.



**Figure 2.** Frozen section of excised hepatic cyst wall taken from the case patient shows hepatocytes with abundant eosinophilic cytoplasm, loose myxoid stroma, and dilated bile ducts.

abdomen (**Figure 1**) revealed a very large hepatic mass, occupying more than two thirds of the upper abdomen. The enlarged liver appeared septated with “cyst-like” spaces, giving the appearance of a multi-lobulated mass. These spaces appeared to contain more dense material than clear fluid. The bowel loops were pushed to the left side of the abdomen.

#### Clinical Course

The patient was admitted for further evaluation of the enlarged liver. Because the CT scan of the liver mass was not consistent with neuroblastoma or hepatoblastoma, the mass was thought to be more likely a mesenchymal hamartoma. Therefore, a pediatric surgical consultation was obtained for possible excision of the mass in the liver. Magnetic resonance imaging

(MRI) also was scheduled for the third hospital day. On day 3 of hospitalization, the patient developed a rectal temperature of 102°F (38.9°C). The abdomen became more distended, now measuring 53 cm. She developed tachypnea and appeared to be in moderate distress.

#### Key Point

Rapidly enlarging abdominal tumors may lead to respiratory embarrassment and may compress the urinary bladder and bowel. Compression on venous channels may cause edema of the lower extremities.

#### Surgical Treatment and Definitive Diagnosis

Blood cultures were drawn and intravenous antibiotics (ceftriaxone and metronidazole) were started. An emergency laparotomy was performed. A cyst occupying the medial aspect of the right lobe of the liver was noted. The cyst was drained (600 mL of gelatinous fluid) and then excised. A diagnosis of cystic mesenchymal hamartoma was made on frozen section (**Figure 2**) and confirmed subsequently on permanent sections. The subsequent course was uneventful, and the patient was discharged home on the tenth postoperative day. The patient is being followed closely since discharge and has not had relapse of the lesion over the past year.

#### HEPATIC TUMORS IN CHILDREN

Hepatic tumors account for only 1% to 4% of all solid tumors in children<sup>1</sup> and include both benign and malignant entities (**Table 3**). The most common malignant tumors in children are hepatoblastoma and hepatocellular carcinoma. Hepatoblastoma is more likely to

occur in a younger child, while hepatocellular carcinoma occurs more frequently in older children. Metastatic lesions, such as neuroblastoma, Wilms' tumor, and lymphoma, are the most common neoplasms seen in the liver of children. Infantile hemangioendothelioma, mesenchymal hamartoma, undifferentiated embryonal sarcoma, and embryonal rhabdomyosarcoma of the biliary tree are less common tumors. Other infrequent tumors seen in the pediatric population include pseudotumors of the liver (uncommon benign lesion of unclear etiology presenting like a malignant tumor) and leiomyosarcoma. Although mesenchymal hamartoma occurs mostly in children, there are rare case reports of this benign entity in adults.<sup>2-4</sup> It is important to note that even benign hepatic tumors can present major challenges in management and rarely can be associated with mortality and morbidity due to their mass effects.

### MESENCHYMAL HAMARTOMA

Maresch first described the entity now recognized as mesenchymal hamartoma in 1903.<sup>5</sup> This lesion was initially described by various names, including lymphangioma, pseudocystic mesenchymal tumor, cystic hamartoma, bile cell fibroadenoma, hamartoma, cavernous lymphangiomatoid tumor, and giant-cell lymphangioma. Edmondson recognized these lesions were similar and coined the term mesenchymal hamartoma in 1956. Approximately 200 cases have been reported.<sup>6</sup>

Up to 90% of the mesenchymal hamartomas affect the right lobe of the liver.<sup>7</sup> It is thought to be a developmental anomaly developing from the ductal plates of the prenatal liver rather than a true neoplasm. It consists of a mixture of mesenchyma, bile ducts, hepatocyte cords, and variably sized cysts. Recent advancements in genetic research demonstrate that a balanced translocation involving a common breakpoint t(19q)(13.4) may be involved.<sup>8</sup>

Mesenchymal hamartoma of the liver is primarily a benign tumor. The most common presentation is an enlarging mass (caused by rapid accumulation of fluid within the lesion) in an otherwise asymptomatic young child. Nearly 85% of hamartoma lesions occur in children under 2 years of age, and only 5% are seen in patients older than 5 years.<sup>9</sup> Boys are affected more frequently than girls (3:2 ratio), and there is no racial predilection.<sup>10</sup> Physical findings are directly related to the size of the lesion and include a protuberant abdomen with dilated superficial veins. The hepatic mass is usually nontender. Rarely, symptoms such as vomiting, decreased appetite, and respiratory distress may accompany the enlarging abdomen. An unusual case of neonatal mesenchymal hamartoma reported in the

**Table 3.** Differential Diagnosis of Common Primary Hepatic Mass

#### Benign lesions

Cavernous hemangioma  
 Choledochal cyst  
 Liver abscess  
 Hydatid cyst  
 Mesenchymal hamartoma  
 Lipoma  
 Angiomyolipoma  
 Benign teratoma

#### Malignant lesions

Hepatoblastoma  
 Hepatocellular carcinoma  
 Yolk-sac tumor  
 Hemangioendotheliosarcoma  
 Metastatic or primary lymphoma  
 Metastatic neuroblastoma  
 Rhabdoid tumor of the liver  
 Extrarenal Wilms' tumor

literature described complications of persistent pulmonary hypertension and renal compromise.<sup>11</sup>

Prenatal diagnosis by ultrasound has been described; the lesions are often small at the time of delivery and enlarge in the first few months of life.<sup>12</sup>

Conditions associated with mesenchymal hamartoma include enlargement of the adrenal gland, small bowel malrotation, neonatal hyperbilirubinemia, fetal hydrops, endocardial fibroelastosis, idiopathic thrombocytopenic purpura, and diffuse endocrinopathy.<sup>13</sup> Neonatal ascites also has been reported in association with a ruptured cystic mesenchymal hamartoma.<sup>14</sup>

Although usually benign, mesenchymal hamartoma may turn malignant in rare instances. de Chadarevian et al<sup>15</sup> reported a case of a 12-year-old girl in whom an undifferentiated sarcoma developed in conjunction with a mesenchymal hamartoma, and the authors postulated a direct link between the two tumors.<sup>15</sup> Ramanujam et al<sup>16</sup> reported the malignant transformation of a mesenchymal hamartoma of the liver into a malignant mesenchymoma. O'Sullivan et al<sup>17</sup> described an undifferentiated embryonal sarcoma arising in a mesenchymal hamartoma.

#### Laboratory Findings

Laboratory parameters usually are nondiagnostic in

mesenchymal hamartoma;  $\alpha$ -fetoprotein (when adjusted for the age of the infant) may be increased in some cases. Erythrocytosis and thrombocytosis that are seen with malignant liver tumors in childhood are not associated with this benign entity.

### Imaging

Ultrasonography may detect the presence of a hepatic mass in utero and in the young infant. It also is helpful in differentiating mesenchymal hamartoma from the other commonly occurring lesions in that age group including hepatoblastoma and infantile hemangiopericytoma.<sup>18</sup> A CT scan can detect the lesions; however, surgical resection is the mainstay of the treatment and detailed anatomy is much better viewed by an MRI, especially if a vascular lesion is considered.<sup>19</sup> CT scan, as seen in this case, can serve as first-line imaging to be followed by MRI if the scan is positive. Lesions appear as large, multilocular, cystic masses with thin internal septations. Occasionally, the solid component of the lesion can be more predominant, with multiple smaller cysts giving the lesion a Swiss-cheese appearance.<sup>20</sup>

### Treatment and Prognosis

Surgical resection, when possible, remains the treatment of choice. There are a few surgical options available, and the procedure chosen must be individualized to the patient. Excision of hamartoma with surrounding rim of normal liver tissue is recommended. For subcapsular lesions, simple enucleation is preferred. Marsupialization of cysts is not commonly performed. Pedunculated tumors are easily resected. Hepatic lobectomy may be the most rational approach when the entire lobe is affected.<sup>21</sup> Spontaneous resolution of a biopsy-proven asymptomatic lesion has been reported.<sup>22</sup> Orthotopic liver transplantation has been used, primarily for lesions in children who are highly symptomatic or are considered to have an unresectable lesion. Although malignant transformations and recurrences are rare, patients with mesenchymal hamartomas should be followed closely.

### CONCLUSION

Mesenchymal hamartoma is important in the differential diagnosis of an enlarged liver in children, but this tumor is very rarely seen in adults. Although it is benign, mesenchymal tumor can be challenging to manage and may become malignant in rare instances. Surgical resection is the treatment of choice. With the advances in genetics, gene therapy may become available for asymptomatic cases in the future. **HP**

### REFERENCES

1. Stocker JT. Hepatic tumors in children. *Clin Liver Dis* 2001;5:259–81, viii–ix.
2. Wada M, Ohashi E, Jin H, et al. Mesenchymal hamartoma of the liver: report of an adult case and review of the literature. *Intern Med* 1992;31:1370–5.
3. Papastratis G, Margaritis H, Zografos GN, et al. Mesenchymal hamartoma of the liver in an adult: a review of the literature. *Int J Clin Pract* 2000;54:552–4.
4. Chung JH, Cho KJ, Choi DW, et al. Solid mesenchymal hamartoma of the liver in adult. *J Korean Med Sci* 1999;14:335–7.
5. Motiwale SS, Karmarkar SJ, Oak SN, et al. Cystic mesenchymal hamartoma of the liver—a rare condition. *Indian J Cancer* 1996;33:157–60.
6. Andy Shau-Bin AC, Kuang-Tse P, Jeng-Hwei T, et al. Mesenchymal hamartoma of liver: a case report. *Chin J Radiol* 2002;27:67–71.
7. Helal A, Nolan M, Bower R, et al. Pathological case of the month. Mesenchymal hamartoma of the liver. *Arch Pediatr Adolesc Med* 1995;149:315–6.
8. Bove KE, Blough RI, Soukup S. Third report of t(19q)(13.4) in mesenchymal hamartoma of liver with comments on link to embryonal sarcoma. *Pediatr Dev Pathol* 1998;1:438–42.
9. Fashir BM, Gawdet S, Al Momen S, Hamid F. Mesenchymal hamartoma in a 21-year-old man. *Pediatr Radiol* 1998;28:514.
10. Stocker JT, Ishak KG. Mesenchymal hamartoma of the liver: report of 30 cases and review of the literature. *Pediatr Pathol* 1983;1:245–67.
11. Mulrooney DA, Carpenter B, Georgieff M, et al. Hepatic mesenchymal hamartoma in a neonate: a case report and review of the literature. *J Pediatr Hematol Oncol* 2001;23:316–7.
12. Dickinson JE, Knowles S, Phillips JM. Prenatal diagnosis of hepatic mesenchymal hamartoma. *Prenat Diagn* 1999;19:81–4.
13. Lack EE. Mesenchymal hamartoma of the liver: a clinical and pathologic study of nine cases. *Am J Pediatr Hematol Oncol* 1986;8:91–8.
14. George JC, Cohen MD, Tarver RD, Rosales RN. Ruptured cystic mesenchymal hamartoma: an unusual cause of neonatal ascites. *Pediatr Radiol* 1994;24:304–5.
15. de Chadarevian JP, Pawel BR, Faeber EN, Weintraub WH. Undifferentiated (embryonal) sarcoma arising in conjunction with mesenchymal hamartoma of the liver. *Mod Pathol* 1994;7:490–3.
16. Ramanujam TM, Ramesh JC, Goh DW, et al. Malignant transformation of mesenchymal hamartoma of the liver: case report and review of the literature. *J Pediatr Surg* 1999;34:1684–6.
17. O'Sullivan MJ, Swanson PE, Knoll J, et al. Undifferentiated embryonal sarcoma with unusual features arising within mesenchymal hamartoma of the liver: report of a case and review of the literature. *Pediatr Dev Pathol* 2001;4:482–9.

(continued on page 38)

(from page 26)

18. Helmberger TK, Ros PR, Mergo PJ, et al. Pediatric liver neoplasms: a radiologic-pathologic correlation. *Eur Radiol* 1999;9:1339–47.
19. Levine E, Wetzel LH, Neff JR. MR imaging and CT of extrahepatic cavernous hemangioma. *AJR Am J Roentgenol* 1986;147:1299–304.
20. Donnelly LF, Bisset GS 3rd. Unique imaging issues in pediatric liver disease. *Clin Liver Dis* 2002;6:227–46, viii.
21. Locham KK, Bal MS, Kapilla AK, Singh M. Cystic mesenchymal hamartoma of liver. *Indian Pediatr* 1999;36:931–5.
22. Barnhart DC, Hirschl RB, Garver KA, et al. Conservative management of mesenchymal hamartoma of the liver. *J Pediatr Surg* 1997;32:1495–8.

Copyright 2003 by Turner White Communications Inc., Wayne, PA. All rights reserved.