

# Wireless Capsule Endoscopy

*Douglas G. Adler, MD*

*Christopher J. Gostout, MD*

In May of 2000, a short paper appeared in the journal *Nature* describing a new form of gastrointestinal endoscopy that was performed with a miniaturized, swallowable camera that was able to transmit color, high-fidelity images of the gastrointestinal tract to a portable recording device.<sup>1</sup> The article highlighted the ability of the device to image the entire small bowel, a prospect that had been difficult with preexisting endoscopic technology. The device, known as the M2A Imaging System (Given Imaging, Atlanta, GA), quickly generated widespread interest within the gastrointestinal community as a means of investigating small bowel disease. The following year, the device was granted approval by the US Food and Drug Administration for use in humans, and it is now widely available in the United States. At present, the exact role of wireless endoscopy is still being defined. Few well-constructed clinical studies have been performed to date to formally assess the indications, sensitivity, specificity, and clinical utility of the device, but some encouraging data from animal studies have been published with regard to the ability of the device to successfully locate small bowel abnormalities.<sup>2</sup> This article reviews the fundamentals of wireless capsule endoscopy. Special attention is paid to the indications, benefits, and drawbacks of the technique, as well as to the strengths and limitations of clinical data available to date.

## THE CAPSULE ENDOSCOPY SYSTEM

The capsule endoscopy system is composed of several key parts: the capsule itself, a portable image receiver/recorder unit and battery pack, and a specially modified computer workstation.

### Wireless Endoscopy Capsule

The imaging capsule is 11 mm by 26 mm, is pill-shaped, and contains these miniaturized elements: a battery, a lens, 4 light-emitting diodes, and an antenna/transmitter (**Figure 1**). The capsule is sealed and resistant to decay within the gut. The capsule comes from the manufacturer ready to use and is activated on removal from a holding assembly, which contains a magnet that keeps the capsule inactive until use. Once activated, the

capsule begins to record images at a rate of 2 per second and transmit them to the belt-pack receiver. The capsule continues to record images at this rate over the course of the 7 to 8 hour image acquisition period, yielding a total of approximately 50,000 images per examination. The capsule's lens is hemispheric and yields a 140-degree field of view, similar to that of a standard endoscope. The capsule is disposable and does not need to be recovered by the patient or medical personnel.

### Receiver/Recorder Unit

In order for the images obtained and transmitted by the capsule endoscope to be useful, they must be received and recorded for study. Patients undergoing capsule endoscopy wear an antenna array consisting of 8 leads that are connected by wires to the recording unit, worn in standard locations over the abdomen, as dictated by a template for lead placement (**Figure 2**). The antenna array is very similar in concept and practice to the multiple leads that must be affixed to the chest of patients undergoing standard 12-lead electrocardiography. The antenna array and battery pack can be worn under regular clothing. The recording device to which the leads are attached is capable of recording the thousands of images transmitted by the capsule and received by the antenna array. Ambulatory (non-vigorous) patient movement does not interfere with image acquisition and recording. A typical capsule endoscopy examination takes approximately 7 hours.

### Computer Workstation

Once the patient has completed the endoscopy examination, the antenna array and image recording device are returned to the health care provider. The recording device is then attached to a specially modified computer workstation, and the entire examination is downloaded into the computer, where it becomes available to the physician as a digital video. The workstation

*(continued on page 17)*

---

*Dr. Adler is an Advanced Endoscopy Fellow and Dr. Gostout is a Professor of Medicine, Department of Internal Medicine, Division of Gastroenterology and Hepatology, Mayo Clinic, Rochester, MN.*

(from page 14)



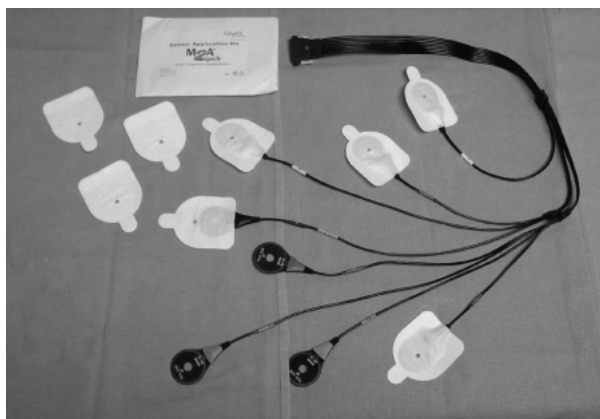
**Figure 1.** The imaging capsule.

software allows the viewer to watch the video at varying rates of speed, to view it in both forward and reverse directions, and to capture and label individual frames as well as brief video clips. Images showing normal anatomy or pathologic findings can be closely examined in full color. A recent addition to the software package is a feature that allows some degree of localization of the capsule within the abdomen and correlation to the video images. Another new addition to the software package automatically highlights capsule images that correlate with the existence of suspected blood or red areas.

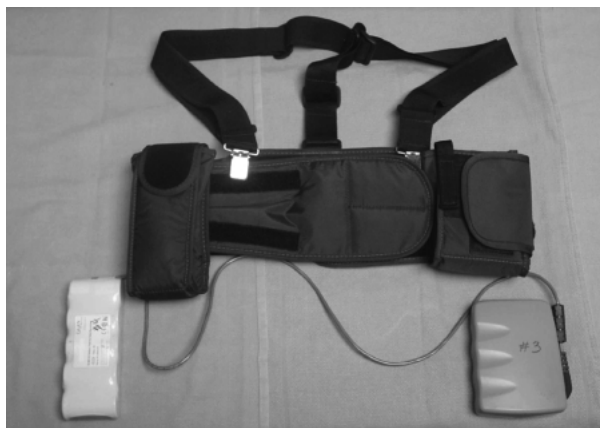#### THE CAPSULE ENDOSCOPY PROCEDURE

A typical capsule endoscopic procedure begins with the patient fasting after midnight on the day before the examination. No formal bowel preparation is required; however, a surfactant (eg, simethicone) may be administered prior to the examination to enhance viewing. After a careful medical examination, the patient is fitted with the antenna array and image recorder. The recording device and its battery pack are worn on a special belt that allows the patient to move freely (**Figure 3**). A fully charged capsule is removed from its holder; once the indicator lights on the capsule and recorder show that data is being transmitted and received, the capsule is swallowed with a small amount of water. At this point, the patient is free to move about. Patients should avoid ingesting anything other than clear liquids for approximately 2 hours after capsule ingestion (although medications can be taken with water). Patients can eat food approximately 4 hours after they swallow the capsule without interfering with the examination.

Seven to 8 hours after ingestion, the examination can be considered complete, and the patient can return the



**Figure 2.** The 8-lead antenna array, which receives images transmitted from the capsule endoscope and transfers them to the image recorder.

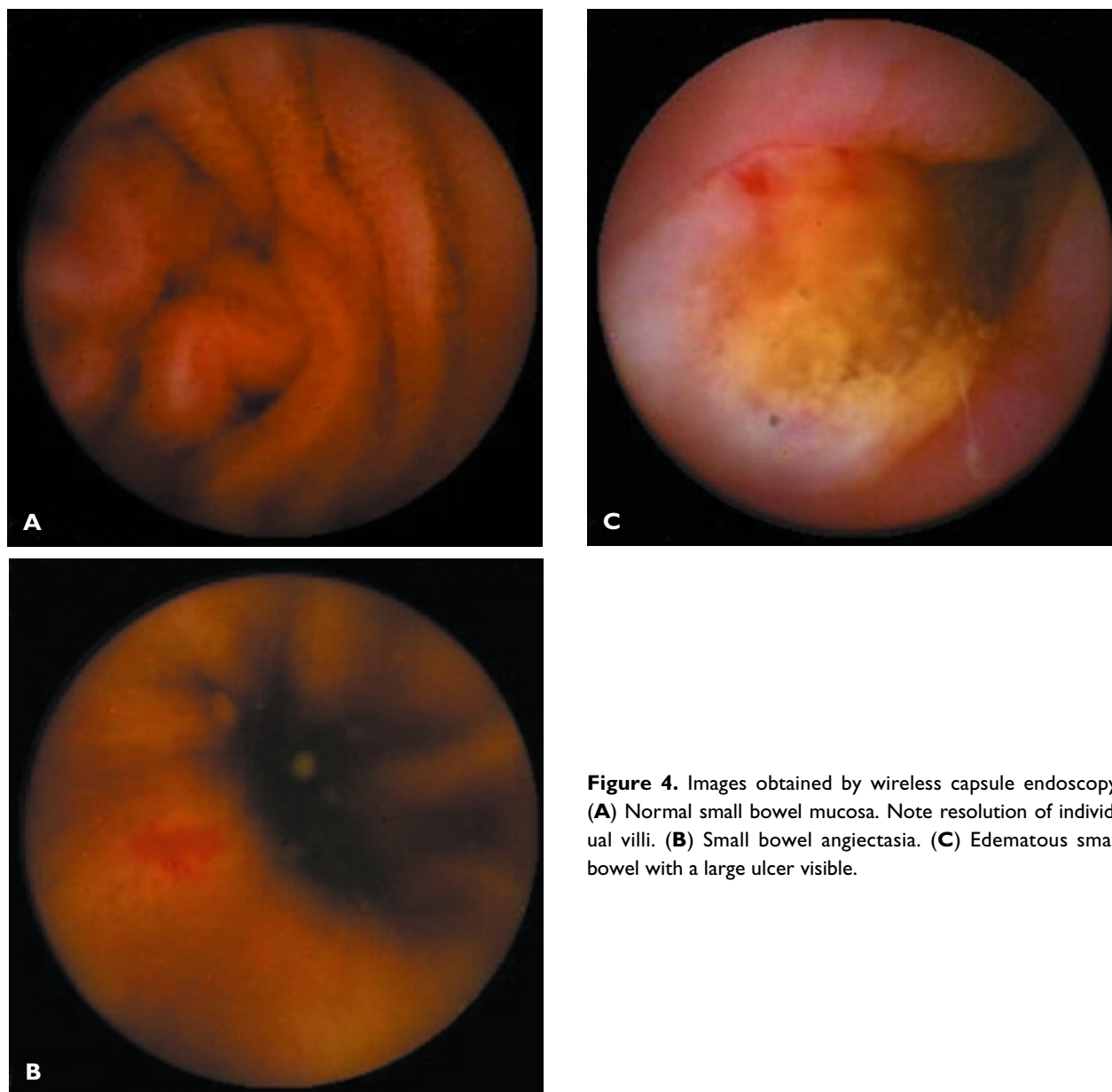


**Figure 3.** The belt and shoulder strap assembly for the image receiver/recorder unit and battery pack.

antenna array and recording device to the physician. It should be noted that gastrointestinal motility is variable among individuals, and hyper- and hypomotility states affect the free-floating capsule's transit rate through the gut. Download of the data in the recording device to the workstation takes approximately 2.5 to 3 hours.<sup>3</sup> Interpretation of the study takes approximately 1 hour. Individual frames and video clips of normal or pathologic findings can be saved and exported as electronic files for incorporation into procedure reports or patient records. **Figure 4** shows some examples of images collected during capsule endoscopy.

#### PROS AND CONS OF CAPSULE ENDOSCOPY

The idea of a capsule wireless endoscope generated a great deal of interest and enthusiasm within the



**Figure 4.** Images obtained by wireless capsule endoscopy. (A) Normal small bowel mucosa. Note resolution of individual villi. (B) Small bowel angiectasia. (C) Edematous small bowel with a large ulcer visible.

gastroenterology community when it was first made available. The capsule offered clinicians a way to visualize the entire small bowel, a region that was previously difficult to view at all, let alone completely. Standard gastroscopes can pass no farther than the second or third part of the duodenum, and push enteroscopy (wherein the patient is intubated per os with a colonoscope or a specially designed enteroscope) often fails to survey the small bowel beyond the midjejunum. Conversely, colonoscopy allows gastroenterologists to view the terminal ileum when entered in a retrograde fashion from the cecum, but usually less than 20 cm of

small bowel can be evaluated in this manner. Sonde enteroscopy, a means to evaluate the entire small bowel endoscopically, is not performed currently for a variety of technical and patient-related reasons.

The need to image the entire small bowel is chiefly important for patients who have ongoing gastrointestinal bleeding from an obscure source and who have had negative results on standard endoscopic evaluations; this problem is encountered frequently in clinical practice. Such patients often must proceed to a variety of increasingly invasive investigations, including small bowel radiographs, angiography, tagged erythrocyte

scans, and, occasionally, intraoperative endoscopy in an effort to identify the source of bleeding.

Capsule endoscopy, with its ability to visualize the entire small bowel, seemed ideally suited for the search for obscure or occult gastrointestinal bleeding in patients who had undergone an inconclusive standard evaluation. The capsule has the ability to obtain high-resolution images of the small bowel mucosa in a relatively noninvasive manner with minimal patient preparation and discomfort.

There are, however, several significant downsides to capsule endoscopy. First and foremost, the device has no therapeutic capabilities. Any lesion discovered via capsule endoscopy that merits treatment must be further investigated (eg, biopsied) or intervened upon with standard medical, endoscopic, radiologic, or surgical techniques. This is true whether the lesion is a tumor, a vascular malformation, or a bleeding ulcer. In addition, whereas standard endoscopes have the ability to insufflate air to distend the bowel (greatly enhancing mucosal visualization), the wireless capsule views the bowel in a functioning, semicollapsed state; this increases the percentage of bowel that is not imaged even as the capsule passes through it. The capsule images are villus-based, which are magnified and significantly different from the standard videoendoscopic images to which most gastroenterologists are accustomed. This presents some challenges in the interpretation of findings, because practitioners must learn to visualize the bowel in a new way. In addition, gastrointestinal motility varies widely in the general population. Although, in most patients, the capsule endoscope successfully passes through the entire small bowel before its battery is exhausted, some patients experience capsule battery depletion while the device is still in the small bowel or, rarely, in the stomach.

Another drawback to capsule endoscopy is the risk of the capsule becoming impacted in a region of stricturing (eg, due to inflammatory bowel disease, surgical adhesions, malignancy) and possibly causing a bowel obstruction. Finally, it is often difficult to discern the exact anatomic location of visualized lesions owing to the fact that the small bowel looks fairly similar throughout its considerable length. A physician reviewing a capsule endoscopy study often must guess whether a lesion is in the duodenum, jejunum, or ileum. Temporal clues (such as recent passage through the pylorus for lesions of the duodenum) are helpful but far from specific. Newer software packages contain a localization feature to assist in assessing the location of specific lesions within the bowel. **Table 1** lists indications and contraindications to capsule endoscopy.

**Table 1.** Indications, Contraindications, and Experimental Roles for Capsule Endoscopy

---

#### **Indications**

Occult or obscure gastrointestinal bleeding  
Chronic gastrointestinal blood loss  
Recurrent overt bleeding in patients with negative results of endoscopic examinations

#### **Contraindications**

Known or suspected obstruction or stricture  
Cardiac pacemakers  
Implanted defibrillators  
Implanted electromechanical devices  
Pregnancy  
Zenker's diverticulum  
Intestinal pseudo-obstruction  
Motility disorders

#### **Experimental indications**

Inflammatory bowel disease  
Small bowel transplantation  
Celiac disease  
Chronic diarrhea of unclear cause

---

### **CLINICAL APPLICATIONS**

#### **Gastrointestinal Bleeding**

**Studies evaluating capsule endoscopy alone.** Capsule endoscopy has been most widely used in patients with chronic gastrointestinal blood loss of unclear origin in whom standard investigations have not been diagnostic. Over the past year, a large amount of data has become available with regard to the outcome of patients in this situation who underwent capsule endoscopy.

Scapa and colleagues<sup>4</sup> published an uncontrolled, retrospective series of 35 patients who underwent capsule endoscopy for unexplained gastrointestinal bleeding in whom there was a suspicion of small bowel disease. All patients had undergone small bowel radiography and some patients had undergone a variety of upper and lower endoscopic procedures, all with negative or inconclusive results. Capsule endoscopy identified abnormal findings in 29 of 35 patients (83%). The most common lesions seen were ulcers, with erosions and angiodysplasia also being very frequently discovered. Among these 29 patients, a definitive source of bleeding was thought to have been discovered in 22 of them (79%).

One of the largest studies presented so far described the results of capsule endoscopy in 66 patients with

chronic gastrointestinal blood loss.<sup>5</sup> A source of bleeding was identified in 39 patients (59%). These lesions were predominately angiectasias, tumors, and ulcers. Similar data were seen by Pennazio and colleagues<sup>6</sup> in a multicenter Italian trial of capsule endoscopy for obscure gastrointestinal bleeding. In this study, 60 patients in whom results of upper and lower endoscopy were negative underwent capsule studies. Capsule endoscopy was able to locate a source of bleeding in 29 patients (48%); angiectasias were the lesion most commonly identified, followed by ulcers and tumors. A variety of similar studies have also been performed.<sup>7-12</sup> In these studies, capsule endoscopy typically led to the discovery of a suspected or presumed source of bleeding in 50% to 80% of patients, on average. It is unclear how many of the lesions identified in these studies were the definitive lesions responsible for the bleeding experienced by these patients versus lesions that were suspected to be the source of bleeding (ie, many patients have asymptomatic angiectasias in the small bowel).

Although these studies are certainly encouraging and preliminarily support the use of the capsule endoscope to identify the source of occult bleeding, it must be stressed that these were for the most part retrospective, uncontrolled trials that, with the exception of the work of Scapa et al,<sup>4</sup> were presented only in abstract form. In addition, data on long-term outcomes (eg, rebleeding rates, complications) are unavailable in most instances.

**Capsule endoscopy versus push enteroscopy.** Perhaps of more clinical value, a smaller number of studies have prospectively compared wireless endoscopy to push enteroscopy in patients with gastrointestinal bleeding. In a recently published pilot study, Lewis and Swain<sup>13</sup> compared the findings of capsule endoscopy to push enteroscopy in 20 patients with obscure gastrointestinal bleeding, all of whom had negative results on at least 1 upper or lower endoscopy or small bowel radiograph (although many had undergone multiple procedures in search of a cause). A positive finding (ie, angiectasia, fresh blood, ulcer, or tumor) was identified during capsule endoscopy in 11 patients (55%), but in 4 of these patients, only fresh blood (and not a discrete lesion) was identified. In contrast, push enteroscopy resulted in the discovery of angiectasia in 6 patients (30%), and all of these patients underwent successful endoscopic therapy of these lesions. Although these results are encouraging, if the cases in which the capsule only visualized fresh blood are discounted, capsule endoscopy had a similar rate for discovering lesions (35%) as did push enteroscopy (30%).

Remke and colleagues<sup>14</sup> compared these 2 modalities in 32 patients in whom a search for a source of bleeding (consisting of upper and lower endoscopy,

angiography, small bowel barium series, and/or scintigraphy) had been undertaken. Conventional studies found a source of bleeding in 5 of 32 patients (15%). Push enteroscopy found a definitive source of bleeding in 7 patients (21%) and questionable sites in an additional 3 patients (9%). Capsule endoscopy found a definitive source of bleeding in 20 patients (62%) and questionable sites in 7 patients (21%) ( $P < 0.05$ ). There were no complications of push enteroscopy or wireless endoscopy in this study.

Dalvaux and colleagues<sup>15</sup> performed a prospective, blinded trial comparing capsule endoscopy to push enteroscopy in 59 patients who had negative results on upper and lower gastrointestinal endoscopies. Fifty-seven patients underwent both push enteroscopy and capsule endoscopy, and 2 patients underwent push enteroscopy but not capsule endoscopy. Some patients had occult blood loss ( $n = 31$ ), whereas others had more overt bleeding ( $n = 26$ ). Lesions were seen in 43 of 57 patients undergoing capsule endoscopy and 32 of 57 patients undergoing push enteroscopy. In 27 patients, the results were identical; in 26 patients, the capsule detected lesions not seen during push enteroscopy, and in 6 patients, push enteroscopy detected lesions missed by capsule endoscopy. There were no complications of either procedure. The improvement in diagnostic yield with capsule endoscopy was statistically significant ( $P = 0.001$ ). The authors of this study concluded that capsule endoscopy found significantly more lesions than push enteroscopy, but they were uncertain of the device's influence on the clinical outcome of these patients.

Van Gossum and colleagues<sup>16</sup> performed capsule endoscopy followed by push enteroscopy in 21 patients who had previously undergone upper and lower gastrointestinal endoscopy with negative results. In this study, push enteroscopy outperformed capsule endoscopy. A total of 19 lesions were found in 15 patients. (The other 6 patients presumably had negative results by both techniques.) Of the 19 lesions, 10 were seen by both capsule endoscopy and push enteroscopy, 6 were only seen during push enteroscopy, and 3 were seen only via capsule endoscopy. All of the lesions seen only with the capsule were in the distal small bowel or the cecum and beyond reach of the push enteroscope.

Finally, in the previously mentioned Italian multicenter study by Pennazio et al,<sup>6</sup> 29 of the 60 patients underwent push enteroscopy in addition to capsule endoscopy. Among the 29 patients who had both procedures performed, push enteroscopy detected a source of bleeding in 8 patients (28%), whereas capsule endoscopy detected a source of bleeding in 17 patients (59%) ( $P < 0.05$ ).

The prospective data comparing capsule endoscopy and push enteroscopy are encouraging but are less robust than are the data generated by the retrospective series evaluating capsule endoscopy alone; 1 of the 5 prospective studies favored push enteroscopy as a diagnostic tool in patients with obscure gastrointestinal bleeding.<sup>16</sup> With the exception of the study by Lewis and Swain,<sup>13</sup> these studies have been presented only in abstract form to date and represent the only comparative data on capsule endoscopy and push enteroscopy available to practitioners.

#### **Capsule Endoscopy Versus Small Bowel Radiography**

In the only published trial of its type to date, Costamagna and colleagues<sup>17</sup> prospectively compared capsule endoscopy to small bowel radiography in a group of 20 consecutive patients who had undergone prior, unrevealing evaluations for a variety of suspected small bowel diseases, including bleeding, inflammatory bowel disease, and small bowel polyps. Small bowel radiographs were normal in 17 of 20 patients and showed ileal nodularity in the remaining 3 patients (15%); 1 of these was found to have Crohn's disease, and the other 2 were thought to have common variable immunodeficiency disease. Capsule endoscopy had positive findings in 17 of 20 patients (85%), most commonly angiectasia (8 of 17) and small bowel polyps (4 of 17). Although the yield of capsule endoscopy compared to small bowel radiography in this study is impressive, it should be noted that small bowel radiography is not considered an appropriate test when angiectasias are considered to be a likely source of a patient's gastrointestinal blood loss. Appropriately, the authors of this study were unsure that in the 13 of 20 patients evaluated for gastrointestinal bleeding, all of whom were found to have angiectasia, the definitive bleeding source had been identified. Correcting for these and other factors, the authors felt that capsule endoscopy was only truly diagnostic in 45% of cases.

#### **Inflammatory Bowel Disease**

In most patients with true inflammatory bowel disease (Crohn's disease or ulcerative colitis), the diagnosis is reached using a combination of upper and lower endoscopy, barium studies, and blood tests. There does exist, however, a small subset of patients in whom the clinical suspicion for inflammatory bowel disease is high and yet results of these tests are negative or normal. Voderholzer and colleagues<sup>18</sup> reported 3 patients in whom the aforementioned evaluations were negative who were found via capsule endoscopy to have Crohn's disease. One patient had an isolated segment

of ileal inflammation; another patient, who had previously been thought to have celiac disease, was found to have a long inflamed jejunoileal segment of intestine; and the third patient was found to have aphthous ulcers in the jejunum and ileum. The authors of this study excluded any patient from capsule endoscopy in whom there was radiographic evidence for stricturing of the small bowel.

#### **Postsurgical Monitoring Following Small Bowel Transplantation**

Patients undergoing small bowel transplantation typically have an end-ileostomy created at the time of surgery. Traditionally, these patients have been monitored for healing, villous recovery, and development of such complications as graft-versus host disease by ileoscopy and biopsy using standard endoscopes. De Franchis and colleagues<sup>19</sup> performed capsule endoscopy in 5 patients who had undergone small intestinal transplant for a variety of reasons, including radiation enteritis, intestinal pseudo-obstruction, and postsurgical short bowel. Capsule studies were performed at various time intervals after transplantation, ranging from 20 days to 7 months. Capsule studies were able to clearly document the time-appropriate changes that would be expected in these patients, ranging from blunted, white, ridge-shaped villi at 20 days posttransplant to the normal-appearing villi expected at 6 months. The authors of this study concluded that capsule endoscopy represents a promising tool for this patient population but were unsure whether the technique provides additional clinical usefulness in comparison to standard retrograde ileoscopy, which also allows biopsies to be obtained.

#### **CONCLUSIONS**

Wireless capsule endoscopy represents a significant technical breakthrough for the investigation of the small bowel, especially in light of the shortcomings of other available techniques to image this region. Capsule endoscopy has the potential for use in a wide range of patients with a variety of illnesses. The definitive role for capsule endoscopy has yet to be determined, and the majority of studies on uses of the device appear only in abstract form to date. At present, capsule endoscopy seems best suited to patients with gastrointestinal bleeding of unclear etiology who have had nondiagnostic traditional testing and in whom the distal small bowel (beyond reach of a push enteroscope) needs to be visualized. The ability of the capsule to detect small lesions that could cause recurrent bleeding (eg, angiectasias, tumors, ulcers) seems ideally suited for this particular role. Therapy (ie, medical, surgical, endoscopic,

radiologic) for any lesions discovered via capsule endoscopy needs to be tailored to the individual patient, and at this time, the capsule has no therapeutic capabilities. Although a wide variety of indications for capsule endoscopy are being investigated, other uses for the device should be considered experimental at this time and should be performed in the context of clinical trials. Care must be taken in patient selection, and the images obtained must be interpreted appropriately and not over-read—that is, not all abnormal findings encountered are the source of the patient's problem. Still, in the proper context, capsule endoscopy can provide valuable information and assist in the management of patients with difficult-to-diagnose small bowel disease. **HP**

## REFERENCES

1. Iddan G, Meron G, Glukhovskiy A, Swain P. Wireless capsule endoscopy. *Nature* 2000;405:417.
2. Appleyard M, Fireman Z, Glukhovskiy A, et al. A randomized trial comparing wireless capsule endoscopy with push enteroscopy for the detection of small-bowel lesions. *Gastroenterology* 2000;119:1431–8.
3. Cave DR. Wireless video capsule endoscopy. *Clin Pers Gastroenterol* 2002;5:203–7.
4. Scapa E, Jacob H, Lewkowicz S, et al. Initial experience of wireless-capsule endoscopy for evaluating occult gastrointestinal bleeding and suspected small bowel pathology. *Am J Gastroenterol* 2002;97:2776–9.
5. Lewis BS. Capsule endoscopy in clinical practice [abstract]. *Gastrointest Endosc* 2002;55:AB125.
6. Pennazio M, Santucci R, Rondonotti E, et al. Wireless capsule endoscopy in patients with obscure gastrointestinal bleeding: results of the Italian multicentre experience [abstract]. *Gastrointest Endosc* 2002;55:AB87.
7. Jensen DM, Dulai G, Lousuebsakul V, et al. Diagnostic yield of capsule endoscopy in patients with severe GI bleeding of obscure origin, subsequent recommendations, and outcomes [abstract]. *Gastrointest Endosc* 2002;55:AB127.
8. Janowski D, Toth L, Wolff R, et al. Video capsule endoscopy: early observations on its role in the diagnosis and management of obscure gastrointestinal bleeding [abstract]. *Gastrointest Endosc* 2002;55:AB128.
9. Lo SK, Fisher HA, Tabibzadeh S, et al. Evaluation of bleeding of undetermined origin by wireless endoscopy [abstract]. *Gastrointest Endosc* 2002;55:AB129.
10. Chutkan RK, Balba NH, Adams TL, Johnson M. Video capsule endoscopy in the evaluation of obscure gastrointestinal bleeding [abstract]. *Gastrointest Endosc* 2002;55:AB133.
11. Mascarenhas-Saraiva MN, Lopes L. Wireless-capsule endoscopy in obscure gastrointestinal bleeding. Worthwhile? [abstract]. *Gastrointest Endosc* 2002;55:AB137.
12. Mylonaki M, Fritscher-Ravens A, Swain PC. Clinical results of wireless capsule endoscopy [abstract]. *Gastrointest Endosc* 2002;55:AB146.
13. Lewis BS, Swain P. Capsule endoscopy in the evaluation of patients with suspected small intestinal bleeding: results of a pilot study. *Gastrointest Endosc* 2002;56:349–53.
14. Remke S, Helou L, Mayer G, Ell C. Wireless capsule endoscopy and push-enteroscopy in chronic gastrointestinal bleeding: a prospective controlled trial [abstract]. *Gastrointest Endosc* 2002;55:AB125.
15. Delvaux MM, Saurin J-C, Gaudin J-L, et al. Comparison of wireless endoscopic capsule and push-enteroscopy in patients with obscure/occult/overt digestive bleeding: results of a prospective, blinded, multicenter trial [abstract]. *Gastrointest Endosc* 2002;55:AB88.
16. Van Gossum A, Francois E, Schmit A, Deviere J. A prospective comparative study between push-enteroscopy and wireless video capsule in patients with obscure digestive bleeding [abstract]. *Gastrointest Endosc* 2002;55:AB88.
17. Costamagna G, Shah SK, Riccioni ME, et al. A prospective trial comparing small bowel radiographs and video capsule endoscopy for suspected small bowel disease. *Gastroenterology* 2002;123:999–1005.
18. Voderholzer WA, Beinhoelzl J, Rogalla P, et al. Is wireless capsule endoscopy useful in diagnosing small bowel Crohn's disease [abstract]? *Gastrointest Endosc* 2002;55:AB139.
19. De Franchis R, Rondonotti E, Abbiati C, et al. Use of the GIVEN video capsule system in small bowel transplanted patients [abstract]. *Gastrointest Endosc* 2002;55:AB129.

**Test your knowledge and  
comprehension of this article with  
Review Questions on page 36.**

Copyright 2003 by Turner White Communications Inc., Wayne, PA. All rights reserved.