

Common Musculoskeletal Problems of the Lower Extremities

Bernard Karnath, MD

Lower extremity joint pain is a commonly reported symptom in the primary care setting. Historical data can often provide clues to the diagnosis. Specifically, the timing and onset of pain, the setting in which pain occurs (along with any aggravating factors), and any history of trauma should all be determined when obtaining patient history. The physical examination can provide further clues leading to a diagnosis. This examination should begin by first observing the patient walking and then inspecting the joint in question. Palpation of the joint for swelling and warmth is also key. Finally, provocative maneuvers can provide final clues helpful in making a diagnosis.

This article, the second in a 3-part series on the musculoskeletal examination, discusses common musculoskeletal conditions of the lower extremities that often lead to joint pain, focusing on examination of the hip, knee, ankle, and foot.

HIP PAIN

Hip pain can be classified as anterior, lateral, or posterior (**Table 1**).¹ Historical information helpful in the diagnosis of hip pain includes recent falls, old age, osteoporosis, use of oral corticosteroids, and a history of cancer. The musculoskeletal examination begins by observation of the patient's gait followed by palpation of the lateral hip to detect evidence of trochanteric bursitis. To detect intra-articular causes of hip pain, the examiner should rotate the hip internally and externally with the patient in the sitting position at the end of the examining table (**Figure 1A**). The Patrick's test (**Figure 1B**) is also a helpful maneuver in the detection of hip pathology. It is performed with the patient in the supine position, with the knee flexed to 90 degrees and the heel placed on the opposite leg on the pretibial region. The examiner then manually pushes down the flexed knee. If pain is elicited, the test is considered positive for intra-articular pathology of the hip, such as osteoarthritis.

Anterior Hip Pain

Anterior hip pain implies intra-articular disease, with osteoarthritis being the most likely diagnosis in patients older than 50 years.¹ Other common causes of anterior hip pain include hip fracture and avascular necrosis of the femoral head. Avascular necrosis is common in patients who have taken corticosteroids, whereas actual fractures are more common among elderly patients with osteoporosis and a history of falling.²

Lateral Hip Pain

Causes of lateral hip pain include trochanteric bursitis, iliotibial band syndrome, meralgia paresthetica, and entrapment of the lateral femoral cutaneous nerve. Patients with trochanteric bursitis report pain when they walk or roll onto their sides.³ On physical examination, palpation of the bursa typically reveals tenderness. Another provocative maneuver involves having the patient abduct the affected leg while lying on the unaffected side; in patients with bursitis, the pain will be exacerbated.

Patients with iliotibial band syndrome also report lateral hip pain. The iliotibial band passes over the greater trochanter. Patients may also report a snapping sensation over the greater trochanter with flexion and extension. Provocative tests for the iliotibial band syndrome include the Ober's test.⁴⁻⁶ This test is performed by having the patient lie on the unaffected side; the affected leg is abducted while the knee is flexed to 90 degrees (**Figure 2**). The leg is then released. An Ober's test is considered positive for iliotibial band syndrome when the thigh is released and the thigh remains abducted.⁶

Patients with meralgia paresthetica most commonly report pain or paresthesias of the lateral hip and thigh. These symptoms are usually exacerbated by exercise.

Dr. Karnath is an Assistant Professor of Internal Medicine, University of Texas Medical Branch, Galveston, TX.

Table 1. Differential Diagnosis of Hip Pain

Anterior hip pain

- Avascular necrosis
- Hip fracture
- Osteoarthritis

Lateral hip pain

- Iliotibial band syndrome
- Meralgia paresthetica
- Trochanteric bursitis

Posterior hip pain

- Lumbar herniated disc
- Sciatica

Finally, the lateral femoral cutaneous nerve is a sensory nerve that can be compressed or entrapped as it passes under the inguinal ligament, thus producing pain or paresthesias.

Posterior Hip Pain

Pain in the posterior hip region commonly occurs as a result of sciatic nerve irritation or nerve root irritation from lumbar disc disease. The sciatic nerve originates from the L4, L5, S1, S2, and S3 nerve roots. The sciatic nerve is susceptible to compression as it passes through the sciatic notch. Patients with sciatica commonly complain of a dull unilateral ache in the buttocks that may radiate down the posterior thigh.

Patients with herniated intervertebral discs typically report lower back pain that radiates down the posterior thigh. The straight-leg raise test is a provocative maneuver that can elicit the pain produced by a herniated disc.⁵ This maneuver will be discussed more fully in the next part of the musculoskeletal examination series on lower back pain. The test is performed with the patient in a supine position. The leg is raised while the knee is extended. The test is considered positive if pain radiating down the posterior thigh is produced at 30 degrees of leg elevation.⁵

KNEE PAIN

Examination of the knee is best conducted with the patient in the supine position.⁷ The knee is first inspected for swelling, erythema, lacerations, bruising, and deformity. The next step is to evaluate for the presence of warmth and effusion by palpation. Warmth and erythema imply infection and/or inflammation.

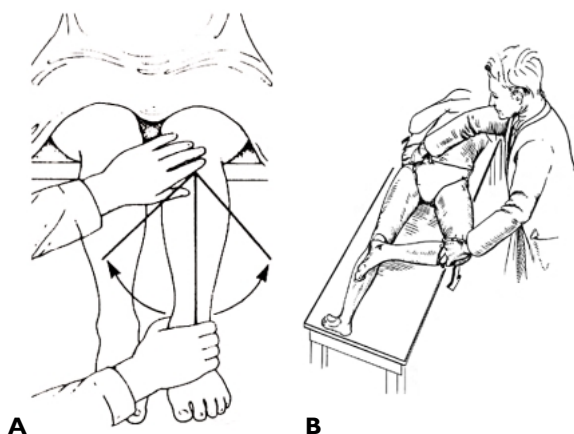


Figure 1. (A) Illustration depicting the test to detect intra-articular causes of hip pain. (B) Illustration of Patrick's test to detect intra-articular hip pathology. (Reprinted from Roberts WN, Williams RB. Hip pain. *Prim Care* 1988;15:786, with permission from Elsevier Science.)

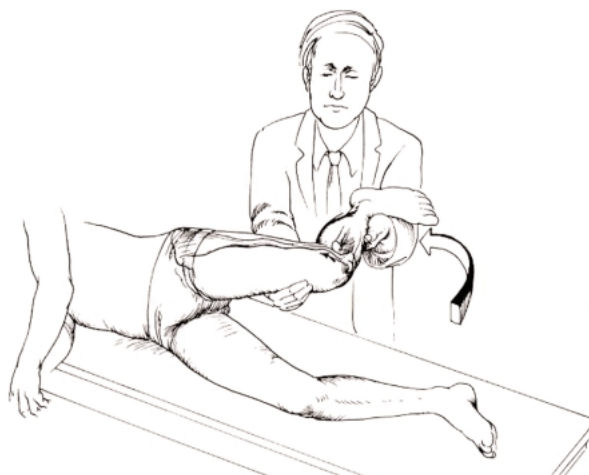

Figure 2. Illustration depicting Ober's test to detect iliotibial band syndrome. (Reprinted with permission from Hoppenfeld S, Hutton R. *Physical examination of the spine and extremities*. New York: Appleton-Century-Crofts; 1976:167.)

Knee Effusions

When elicited, the bulge sign (**Figure 3A**) and balloon sign (**Figure 3B**) are helpful in the detection of knee effusions.^{8–10} Both signs are elicited with the knee in the extended position. The bulge sign is elicited by placing one hand above the knee and pushing the fluid downward and laterally. Then the knee is tapped

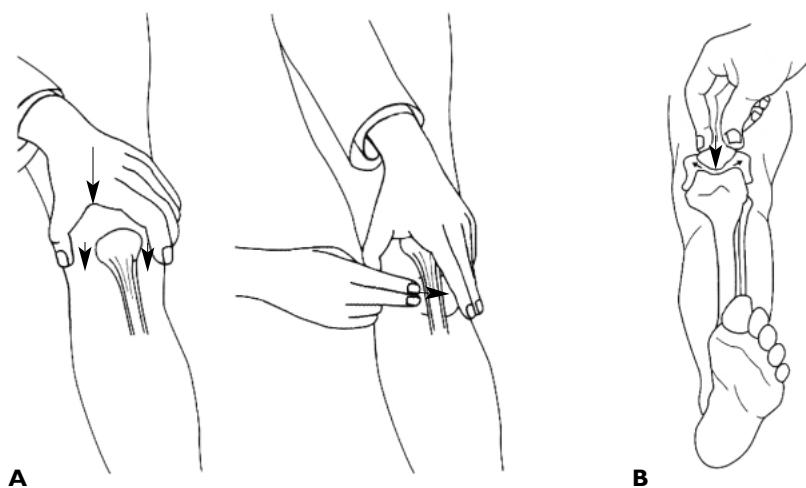


Figure 3. (A) Illustration depicting the test to elicit the bulge sign. (B) Illustration depicting the test to elicit the balloon sign. (Redrawn with permission from Bickley LS, Hoekelman RA. *Bates' guide to physical examination and history taking*. 7th ed. Philadelphia: Lippincott-Raven; 1999:533–4.)

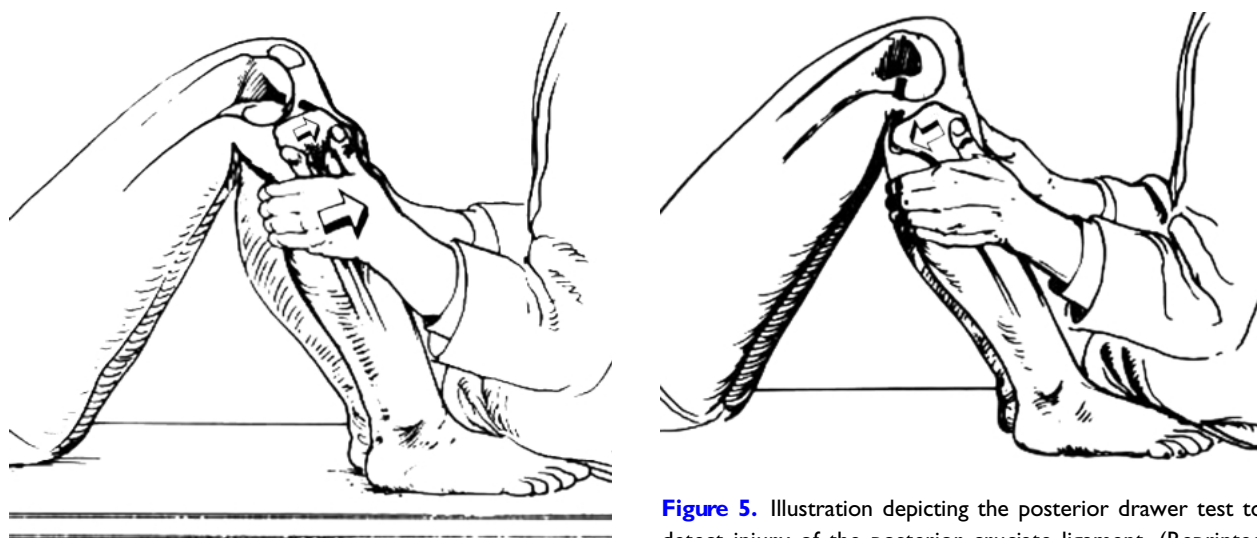


Figure 4. Illustration depicting the anterior drawer test to detect injury of the anterior cruciate ligament. (Reprinted with permission from Hoppenfeld S, Hutton R. *Physical examination of the spine and extremities*. New York: Appleton-Century-Crofts; 1976:186.)

Figure 5. Illustration depicting the posterior drawer test to detect injury of the posterior cruciate ligament. (Reprinted with permission from Hoppenfeld S, Hutton R. *Physical examination of the spine and extremities*. New York: Appleton-Century-Crofts; 1976:186.)

with the opposite hand on the lateral side. A fluid wave on the medial side confirms an effusion. The balloon sign is elicited by compressing the patella against the femur. A balloon sign is considered positive when fluid is ejected into the spaces adjacent to the patella. Effusions can be caused by conditions such as osteoarthritis, trauma, infection, and gout.

Ligamentous Injuries

Knee trauma is a common reason for visiting a physician. However, most knee injuries are not associated with a fracture.^{6,7} Therefore, the focus of the examina-

tion in a patient who has experienced knee trauma should be on ligamentous stability.¹¹

The anterior cruciate ligament is frequently injured during acute deceleration. The stability of the anterior cruciate ligament can be assessed by using the anterior drawer test (Figure 4) or Lachman's test.¹² Both tests are conducted with the patient in the supine position. The anterior drawer sign is elicited with the knee in 90 degrees of flexion and the patient's foot stabilized; an attempt is then made to slide the tibia anteriorly. Detectable motion signifies a positive drawer sign and thus laxity of the anterior cruciate ligament. Lachman's test is a similar maneuver performed with the knee in 20 degrees of flexion.¹² The femur is stabilized with one

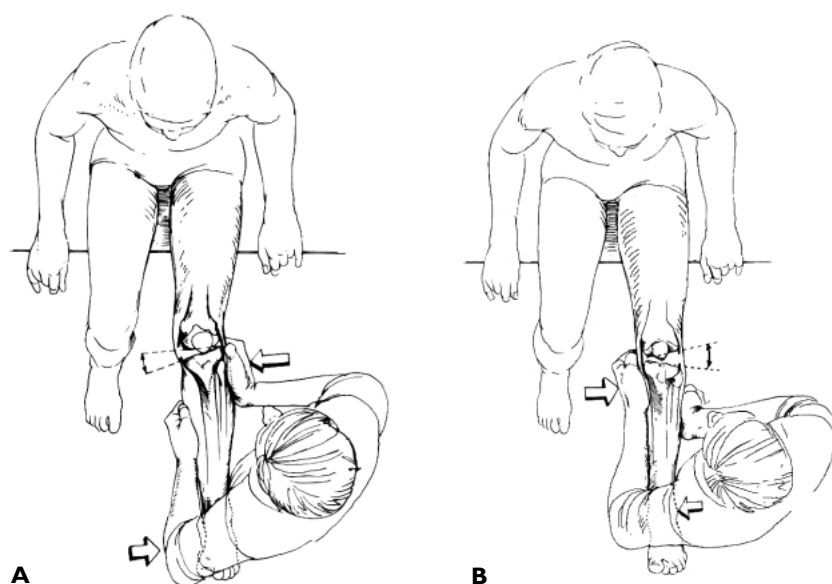


Figure 6. Illustration depicting the method to detect laxity of the medial collateral ligament (**A**) and the lateral collateral ligament (**B**). (Reprinted with permission from Hoppenfeld S, Hutton R. *Physical examination of the spine and extremities*. New York: Appleton-Century-Crofts; 1976:185.)

hand while the other hand attempts to move the tibia forward.

The posterior cruciate ligament is frequently injured during a blow to the anterior proximal tibia while the knee is flexed. The posterior drawer sign, which indicates laxity of this ligament, is elicited in a similar manner to the anterior drawer sign, with the exception that an attempt is made to slide the tibia posteriorly (**Figure 5**).¹² In addition, the sag test can be performed on a patient in the supine position with the hips flexed to 45 degrees and knees flexed to 90 degrees. The tibia will sag or drop back if an injury to the posterior cruciate ligament has occurred.

The medial collateral ligament can be tested for laxity by applying valgus stress at the knee (ie, by pushing medially against the knee and pulling laterally at the ankle) (**Figure 6A**). Pain or a gap in the medial joint suggests ligamentous laxity. The lateral collateral ligament can similarly be tested for laxity by applying varus stress (ie, pushing laterally at the ankle while pulling medially at the knee) (**Figure 6B**).

Meniscal injury can be detected by performing the McMurray's test (**Figure 7**).¹² The patient's knee is flexed and then slowly extended while the tibia is held in internal or external rotation. A pop or click heard during palpation along the medial joint line suggests meniscal injury.

ANKLE PAIN

Ankle pain frequently results from acute injury. The most common mechanism of ankle injury is plantar flex-

ion and inversion,¹³ and the most commonly injured ligaments are the anterior talofibular ligament and the calcaneofibular ligament.

The anterior drawer test can also be used to assess the stability of the anterior talofibular ligament (**Figure 8**).⁶ The examiner stabilizes the tibia and fibula with one hand and applies anterior force to the calcaneus and talus with the other hand. Anterior displacement of the talus indicates a possible sprain of the anterior talofibular ligament.

The talar tilt test can be used to assess the stability of the calcaneofibular ligament (**Figure 9**).⁶ The examiner stabilizes the distal tibia with one hand while grasping the talus with the other. The examiner then tilts the talus into an adducted position. Movement toward the adducted position that is greater in the involved foot than in the noninvolved foot indicates a probable tear of the calcaneofibular ligament.

FOOT PAIN

Foot pain can be localized to the forefoot, the midfoot, and the hindfoot. **Table 2** provides the differential diagnosis of pain in each of these areas.

Forefoot

Metatarsalgia is a term used to describe pain in the plantar surface of the forefoot.¹⁴ The pain typically worsens with weight bearing and is relieved by rest. Patients describe this pain as feeling similar to walking with a pebble in the shoe. Palpation of the metatarsal heads generally reveals tenderness in the involved

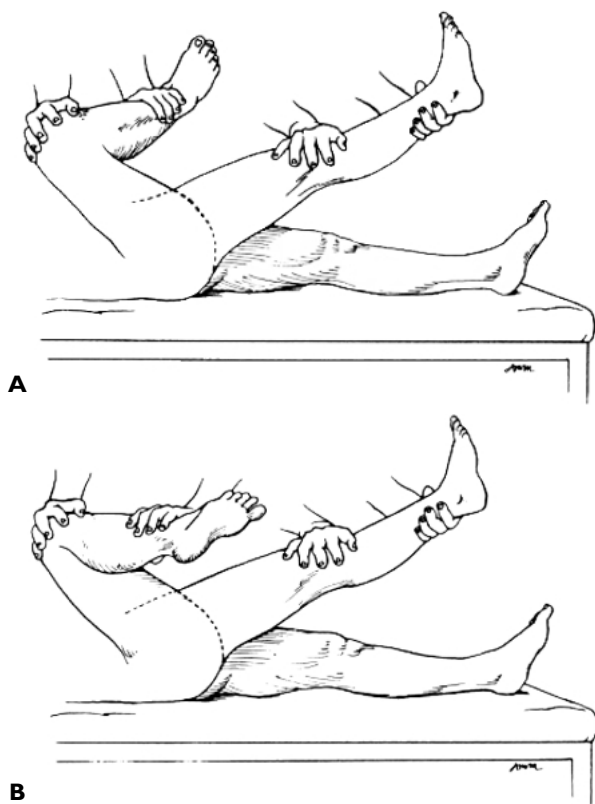


Figure 7. Illustration depicting McMurray's test to detect meniscal injury. (A) Method used to detect tears of the lateral meniscus. (B) Method used to detect tears of the medial meniscus. The maneuver is performed by flexing the knee of a supine patient while holding the tibia in internal (A) or external (B) rotation and then slowly extending the knee. A palpable snap heard as the knee is extended suggests a tear in the meniscus. (Reprinted with permission from Judge RD, Woolliscroft JO, Zelenock GB, Zuidema GD. *The Michigan manual of clinical diagnosis*. Philadelphia: Lippincott-Raven; 1998:297.)

metatarsals. Plantar keratoses are common in areas of excessive stress, such as the second metatarsal head; metatarsalgia is also common in this area.

Morton's neuroma, also known as *intermetatarsal neuroma*, is another cause of forefoot pain.¹⁴ Morton's neuroma is a perineural fibrotic lesion of a common digital nerve. The pain typically occurs in the intermetatarsal region between the third and fourth toes. The pain is worse with shoe wear and better with rest and shoe removal. Mulder's sign is a useful diagnostic aid in cases of Morton's neuroma and is elicited by applying pressure to the medial and lateral aspects of the forefoot, thereby compressing the neuroma between metatarsals while simultaneously compressing

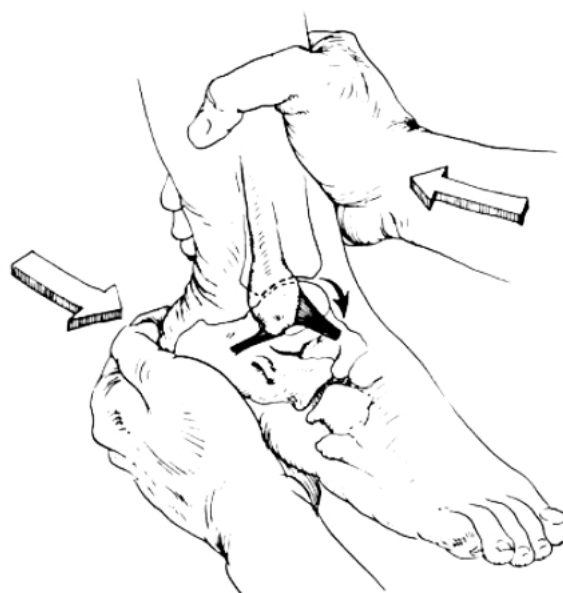


Figure 8. Illustration depicting the anterior drawer test to assess the stability of the anterior talofibular ligament. (Reprinted with permission from Hoppenfeld S, Hutton R. *Physical examination of the spine and extremities*. New York: Appleton-Century-Crofts; 1976:227.)

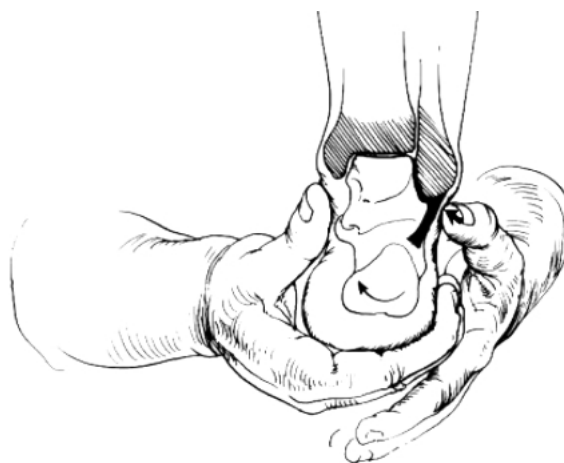

Figure 9. Illustration depicting the talar tilt test to assess stability of the calcaneofibular ligament. (Reprinted with permission from Hoppenfeld S, Hutton R. *Physical examination of the spine and extremities*. New York: Appleton-Century-Crofts; 1976:227.)

the neuroma between the thumb and index finger of the other hand.¹¹ A click and pain produced by this maneuver constitute a positive sign.

A common condition affecting the forefoot, gout is usually localized to the metatarsophalangeal joint of

Table 2. Differential Diagnosis of Foot Pain

Forefoot

Gout

Metatarsalgia

Morton's neuroma

Midfoot

Plantar fasciitis

Hindfoot

Achilles tendonitis

the great toe. On inspection, the metatarsophalangeal joint of the great toe is greatly inflamed and edematous (**Figure 10**). There is associated pain in the great toe, which is referred to as *podagra*.

Midfoot

Plantar fasciitis is a common cause of midfoot pain. Palpation of the medial calcaneal tubercle reproduces the pain.¹⁵ Pain is located in the inferior medial aspect of the calcaneus. Patients report pain on taking the first several steps of the day, with symptoms lessening as walking continues. In patients with plantar fasciitis, subcalcaneal bone spurs are generally found in 25% of cases,¹⁶ although one study reported finding such bone spurs in 70% of cases.¹⁷

Hindfoot

Common causes of hindfoot pain include Achilles tendonitis and retrocalcaneal bursitis, both of which present with pain, erythema, and warmth.¹⁴ The pain of retrocalcaneal bursitis can be exacerbated by dorsiflexion, which causes compression of the bursa. Achilles tendonitis can also present with weakness that is exacerbated by activity. Achilles tendonitis must be distinguished from tendon rupture. The Thompson test is a helpful maneuver to detect Achilles tendonitis. This test is performed with the patient in a prone position with the heels placed over the edge of the table. The examiner then squeezes the gastrocnemius-soleus complex. A normal response is for the foot to plantarflex. Absence of plantar flexion indicates a tear of the Achilles tendon. **HP**

REFERENCES

1. Roberts WN, Williams RB. Hip pain. *Prim Care* 1988;15:783–93.

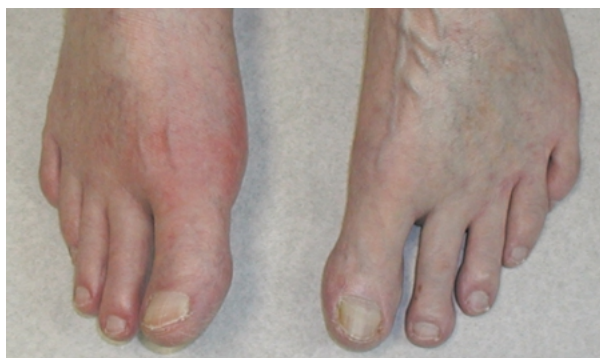

Figure 10. Clinical photograph showing gout of the right great toe.

2. O’Kane JW. Anterior hip pain. *Am Fam Physician* 1999;60:1687–96.

3. Kalb RL. Evaluation and treatment of hip pain. *Hosp Pract (Off Ed)* 1998;33:131–2, 135–6.

4. Adkins SB 3rd, Figler RA. Hip pain in athletes. *Am Fam Physician* 2000;61:2109–18.

5. Judge RD, Woolliscroft JO, Zelenock GB, Zuidema GD. *The Michigan manual of clinical diagnosis*. Philadelphia: Lippincott-Raven; 1998.

6. Hoppenfeld S, Hutton R. *Physical examination of the spine and extremities*. New York: Appleton-Century-Crofts; 1976.

7. McCune WJ, Matteson EL, MacGuire A. Evaluation of knee pain. *Prim Care* 1988;15:795–808.

8. Bickley LS, Hoekelman RA. *Bates’ guide to physical examination and history taking*. 7th ed. Philadelphia: Lippincott-Raven; 1999.

9. Tandeter HB, Shvartzman P. Acute knee injuries: use of decision rules for selective radiograph ordering. *Am Fam Physician* 1999;60:2599–608.

10. Johnson MW. Acute knee effusions: a systematic approach to diagnosis. *Am Fam Physician* 2000;61:2391–400.

11. McRae R. *Clinical orthopaedic examination*. 4th ed. New York: Churchill Livingstone; 1997.

12. Konin JG, Wiksten DL, Isear JA. *Special tests for orthopedic examination*. Thorofare (NJ): Slack; 1997.

13. Wolfe MW, Uhl TL, Mattacola CG, McCluskey LC. Management of ankle sprains [published erratum appears in *Am Fam Physician* 2001;64:386]. *Am Fam Physician* 2001;63:93–104.

14. Stern SH. Ankle and foot pain. *Prim Care* 1988;15:809–26.

15. Barrett SL, O’Malley R. Plantar fasciitis and other causes of heel pain. *Am Fam Physician* 1999;59:2200–6.

16. Gibbon WW, Long G. Ultrasound of the plantar aponeurosis (fascia). *Skeletal Radiol* 1999;28:21–6.

17. Onuba O, Ireland J. Plantar fasciitis. *Ital J Orthop Traumatol* 1986;12:533–5.