

# Unusual Presentations of Prostatic Adenocarcinoma: Lymph Node Metastasis

*Parthas Narasimhan, MD, FACP, FRCP(C)*

*Ibrahim F. Hitti, MD, FCAP*

*Aamir Awan, MD*

*Meghna Desai, MD*

*Barry F. Kanzer, MD*

*Elizabeth McDonald, MD*

**C**arcinoma of the prostate is the most frequently diagnosed visceral cancer in men in the United States.<sup>1</sup> Age, ethnicity, family history, and dietary fat intake are the most widely cited risk factors.<sup>2</sup> This cancer is known to spread via 3 mechanisms: (1) local extension, (2) extension through the lymphatic system, and (3) extension through the blood stream along the vertebral venous plexus. Ordinarily, patients with untreated or hormone-resistant prostatic cancer initially develop pelvic lymph node metastases and spinal bony metastases in the lumbosacral spine. Further spread usually involves the axial skeleton and is associated with bone pain, anemia, weight loss, a diminished quality of life, and death.

This article reports on 2 cases of prostatic adenocarcinoma (PAC) that manifested as massive lymphadenopathy with compression of the common bile duct (patient 1) and compression of the trachea (patient 2); the sparing of the skeleton and the pelvic lymph nodes was noticeable in both cases. The clinical characteristics of PAC are discussed, as is metastasis of the disease.

## CASE PRESENTATIONS

### Patient 1

A 64-year-old white man was admitted to the hospital with jaundice, dark urine, clay-colored stools, pruritus, and weight loss. Pertinent findings from the physical examination included scleral icterus, scratch marks over the skin, and a vague right upper quadrant abdominal mass. Rectal examination revealed a firm nodule on the right lateral lobe of the prostate. Pertinent laboratory findings included the following serum levels: albumin, 3.2 g/dL; alkaline phosphatase, 261 U/L; aspartate aminotransferase (AST, SGOT), 100 U/L; alanine

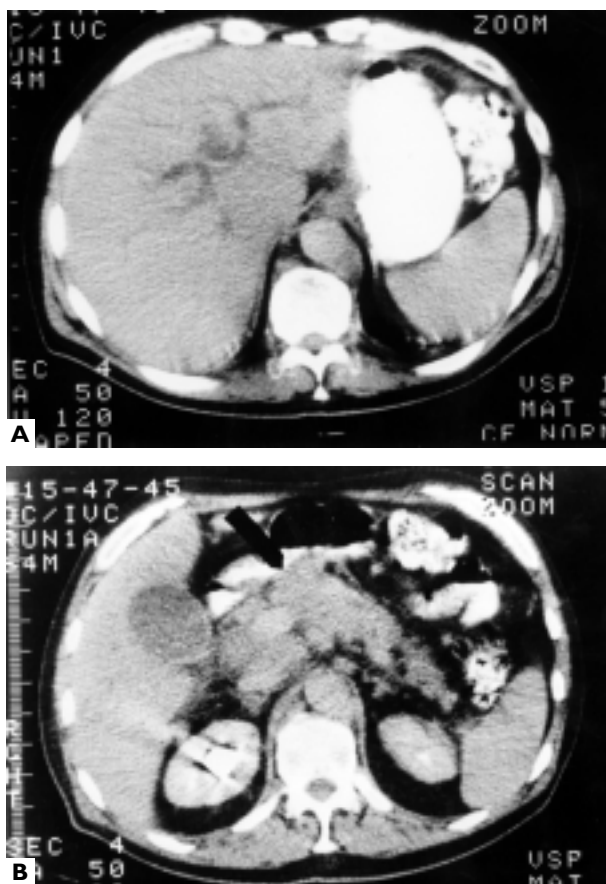
aminotransferase (ALT, SGPT), 81 U/L; total bilirubin, 11.3 mg/dL; direct bilirubin, 9.3 mg/dL; and prostate-specific antigen (PSA), 493 ng/mL. Leukocyte count was  $5.6 \times 10^3/\text{mm}^3$  (with a normal differential), hemoglobin level was 12.4 g/dL, and hematocrit was 39.8%.

Abdominal ultrasonography showed a possible mass in the head of the pancreas and lymphadenopathy in the porta hepatis. Computed tomography (CT) scans of the abdomen (**Figure 1**) showed a dilated intrahepatic biliary tree and a distended gallbladder. Endoscopic retrograde cholangiopancreatography was performed with stent placement (**Figure 2**). CT-guided fine needle aspiration of the mass in the right upper quadrant yielded adenocarcinoma cells of probable prostatic origin, and analysis of a transrectal prostate biopsy specimen showed PAC (**Figure 3**). A bone scan revealed no evidence of any metastatic disease.

The patient was started on a continuous regimen of leuprolide (7.5-mg injection intramuscularly every month) and flutamide tablets (250 mg 3 times daily). His PSA level decreased, the mass in the right upper quadrant regressed, and the jaundice resolved. Six months later, however, the patient returned to the hospital with

---

*Dr. Narasimhan is a Clinical Assistant Professor, Weill Medical College, Cornell University, New York, NY; and Chief, Division of Hematology/Oncology, North Shore University Hospital, Forest Hills, NY. Dr. Hitti is a Clinical Assistant Professor, Department of Pathology, SUNY Downstate Medical Center, Brooklyn, NY; and the Laboratory Medical Director, North Shore University Hospital, Forest Hills, NY. Dr. Awan is the former Chief Medical Resident, Dr. Desai is a third-year resident in Internal Medicine, and Dr. Kanzer is the Director, Department of Radiology, North Shore University Hospital, Forest Hills, NY. Dr. McDonald is the former Director, Department of Medicine, North Shore University Hospital, Forest Hills, NY; and the current Associate Medical Director, UMDNJ University Hospital, Newark, NJ.*



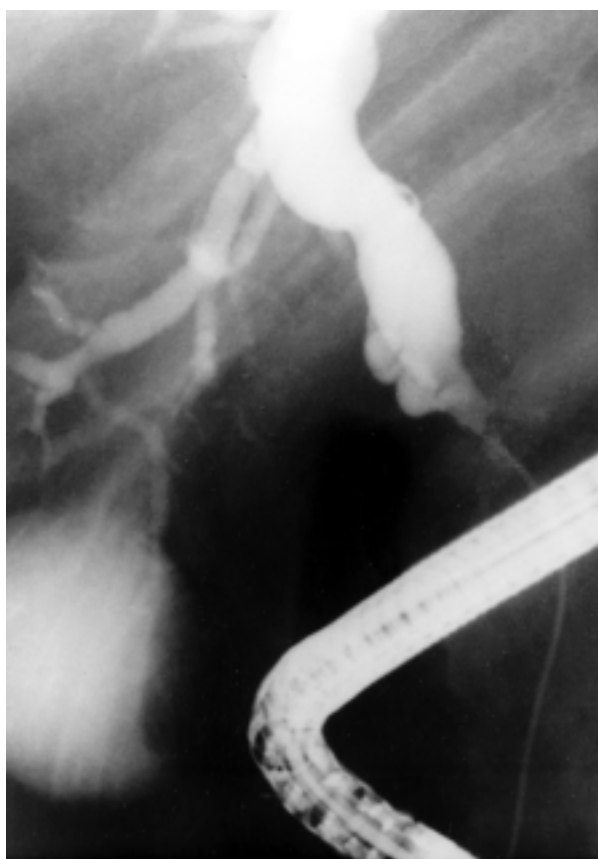**Figure 1.** Contrast enhanced computed tomography scans of patient 1's abdomen showing a dilated intrahepatic biliary tree (A) and lymphadenopathy in the porta hepatis with a distended gallbladder (B).

recurrent progressive disease. He refused further therapy and subsequently died.

## Patient 2

A 75-year-old white man was found to have a prostatic nodule during routine physical examination. PSA level was 6.9 ng/mL (normal, 0–4 ng/mL). Analysis of material from a core needle biopsy of the prostate showed adenocarcinoma. The patient was treated with external beam radiotherapy, and the PSA level decreased to 5 ng/mL.

One year later, the patient's PSA level began to rise, reaching levels of 14 ng/mL and 23 ng/mL. The patient was started on hormonal treatment with leuprolide and flutamide, and his PSA level decreased to less than 1 ng/mL. CT scans of the abdomen and pelvis and a bone scan showed no evidence of any metastatic disease. The patient was considered to be in clinical remission.



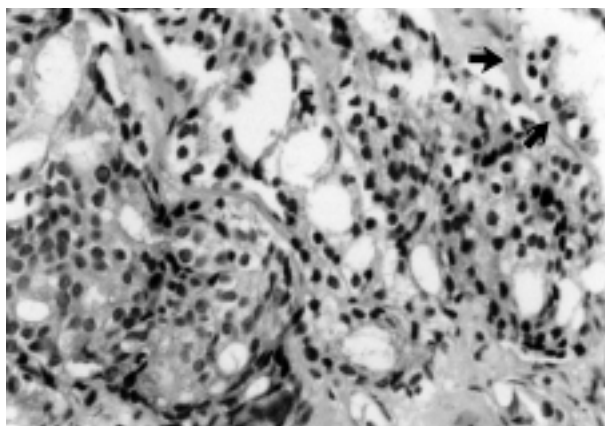
**Figure 2.** Endoscopic retrograde cholangiopancreatography scan from patient 1 showing an obstructed and dilated proximal common bile duct caused by the lymphadenopathy seen in Figure 1.

Six years later, the patient developed right-sided cervical lymphadenopathy. PSA level was 18 ng/mL. Neck biopsy results revealed adenocarcinoma of likely prostatic origin (Figure 4). A repeat bone scan was negative for the presence of metastatic disease. Because the patient could not tolerate flutamide, he was restarted on leuprolide and also given bicalutamide. The cervical lymph nodes regressed in size, but the patient developed dyspnea and stridor. He was found to have extensive mediastinal lymph node involvement resulting in compression of the trachea (Figure 5). Emergency radiotherapy was begun, and the stridor and dyspnea improved over the course of 3 weeks. Nevertheless, the disease progressed, eventually resulting in death.

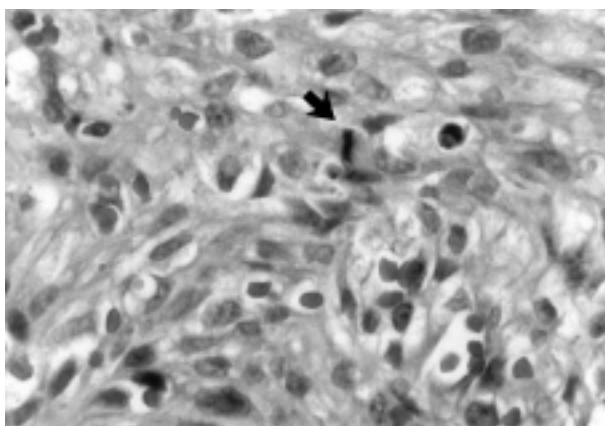
## DISCUSSION

### Epidemiology

PAC is the most common cancer diagnosed in men, accounting for 12.3% of male cancer deaths. It



**Figure 3.** Photomicrograph of prostatic core needle biopsy material from patient 1 illustrating a back-to-back growth pattern of neoplastic glandular structures (Gleason's grade 4). For comparison, a benign glandular acinus can be seen in the upper right-hand corner (arrows) (hematoxylin-eosin, original magnification  $\times 200$ ).

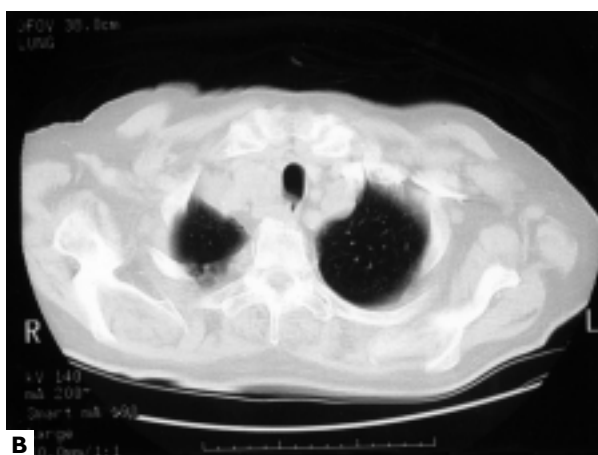
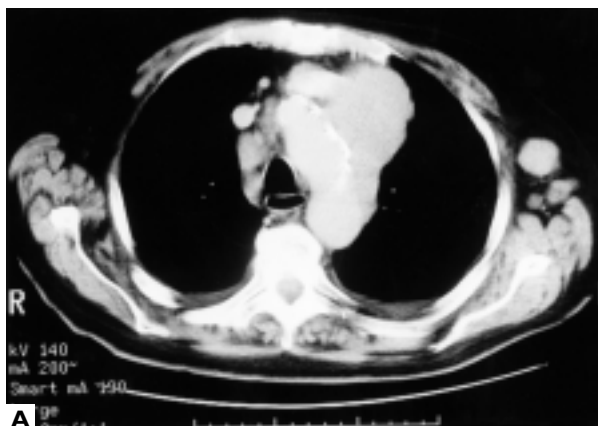


**Figure 4.** Photomicrograph of a biopsy specimen from the right neck mass in patient 2 showing a solid proliferation of carcinoma cells with vesicular nuclei and prominent nucleoli; a mitotic figure can be seen in the center of the field (arrow) (hematoxylin-eosin, original magnification  $\times 400$ ).

was estimated that 198,100 men would be diagnosed with PAC in 2001 and that 31,500 deaths would occur from the disease.<sup>3</sup>

#### Common Clinical Manifestations

In most cases, the presenting symptom of PAC involves urinary tract obstruction. However, the presence of PAC can also be heralded by symptoms located farther from the prostate; in these cases, patients most often report back pain, leading to a diagnosis of



**Figure 5.** Contrast-enhanced computed tomography (CT) scan of the chest from patient 2 showing tracheal displacement and narrowing secondary to right superior mediastinal lymphadenopathy. (A) CT soft-tissue/bone window. (B) CT lung window.

metastatic disease of the axial skeleton.<sup>4</sup> Cancerous spread to the liver and the lungs occurs less commonly.<sup>5</sup> **Table 1** summarizes the incidence of metastatic PAC in various organs, as determined from autopsy series. **Table 2** details the patterns of involvement in the 3 organs most commonly affected by metastatic PAC. Lymph node metastases that do not involve vital structures are easily managed. However, when nodal disease compresses vital organs, there can be serious clinical consequences.

#### Uncommon Clinical Manifestations

**Skip lymphadenopathy.** Whereas the spread of cancer cells to local pelvic lymph nodes is common, supraclavicular and mediastinal lymph node involvement is much less prevalent. Patient 1 was completely asymptomatic

**Table 1.** Incidence of Metastatic Adenocarcinoma of the Prostate in Various Organs

Organ	Incidence
Pelvic lymph nodes	85%
Bone	65%–85%
Lung	49%
Liver	36%
Adrenal glands	17%
Kidney	11%

Data from Elkin and Mueller,<sup>6</sup> Jacobs,<sup>7</sup> and Saitoh et al.<sup>8</sup>

until lymph node metastases of the porta hepatis compressed the common bile duct and caused obstructive jaundice. Similarly, although patient 2's lymph node metastases of the right supraclavicular area were managed successfully with hormonal treatment, the subsequent development of massive lymphadenopathy in the mediastinum caused life-threatening tracheal compression, stridor, and dyspnea.

**Table 3** is a condensed summary of the published cases of PAC involving skip lymphadenopathy. Butler and colleagues<sup>12</sup> reported that among a series of 19 patients with supraclavicular lymph node metastasis, 18 had involvement of left supraclavicular lymph nodes; only 1 had right-sided involvement. Saeter and colleagues<sup>13</sup> concluded in their review of 47 cases that left-sided supraclavicular lymphadenopathy was the most common type of nonregional lymphatic spread by PAC. Presumably, cancerous cells reach the supraclavicular nodes of the left side via the thoracic duct, in a fashion similar to that of testicular cancer. Superior vena cava obstruction<sup>14</sup> and compression of the trachea (with dyspnea)<sup>15</sup> caused by metastasis of PAC to mediastinal lymph nodes have also been reported.

Involvement of the mediastinal lymph nodes has to be massive to cause tracheal compression and resultant stridor, as occurred in patient 2. Two unusual features of metastatic nodal sites were observed in this patient, namely, the right-sided nature of the supraclavicular nodal involvement and the massive mediastinal involvement. Parenthetically, 1 case of laryngeal stridor caused by PAC metastases in the larynx has also been described.<sup>16</sup>

**Obstructive jaundice.** PAC with biliary signs and symptoms is the most unusual presentation of the disease. Jaundice in cases of PAC is usually associated with metastatic parenchymal liver disease and abnormal results on liver function tests; it generally indicates a

poor prognosis.<sup>17</sup> **Table 4** lists 3 published cases of PAC associated with jaundice that do not involve metastatic parenchymal liver disease. Bloch and Block<sup>17</sup> reported a case of PAC with obstructive jaundice secondary to carcinomatous involvement of the common bile duct. Reddy and colleagues<sup>18</sup> described intermittent intrahepatic cholestasis as one of the nonmetastatic complications of PAC. Recently, Cole and colleagues<sup>19</sup> reported a case of PAC with obstructive jaundice secondary to marked retroperitoneal, peripancreatic, and peri-aortic lymphadenopathy.

In the literature, there are no previous reports of PAC and obstructive jaundice secondary to compression of the porta hepatis. Patient 1's case corroborates the observation that patients with PAC and jaundice caused by extrahepatic obstruction have a better prognosis than those with parenchymal hepatic disease.<sup>17</sup>

### Metastasis of Prostatic Adenocarcinoma

The prognosis of all cancer patients depends on the capacity of their malignant cells to disseminate, take root, and flourish in distant sites of the body. The main determinant of metastatic spread is the adhesiveness of the tumor cells; the best studied example of such a determinant is the lymphocyte-homing receptor, also known as antigenic determinant CD44. This entity is a cell surface glycoprotein that governs the normal trafficking of lymphocytes from the blood to lymphatic tissues. Some splicing variants of this protein confer metastatic potential to lymphoma cells.<sup>20</sup> Once a tumor cell becomes detached and enters the lymphatic space or the blood stream, microenvironmental selective pressure and hemodynamic factors are major determinants of the metastatic pattern of a malignant neoplasm.

Hemodynamic factors depend on the anatomic characteristics of a particular organ. More specifically, they are related to the fact that organs seeded with the largest number of tumor cells will develop the greatest number of metastases. This fact explains the preponderance of pelvic node (spread by lymphatic drainage) and lower spinal column (spread by prevertebral venous plexus drainage) metastases from PAC.<sup>21</sup>

Multiple microenvironmental factors are equally important and include local growth factors, chemotactic substances, extracellular matrix, and membrane adherence receptors of the endothelial cells of a particular target organ. Cases of metastatic colon carcinoma that spare the liver, the affinity of some gastric cancers to metastasize to the ovaries, the rarity of metastases to a highly perfused organ (eg, the spleen), and the clinically insignificant hematogenous spread of metastatic

**Table 2.** Patterns of Involvement of Metastatic Adenocarcinoma of the Prostate

Pelvic Lymph Node Metastasis*	Bone Metastasis†	Lung Metastasis‡
Obturator-hypogastric region (95%)	Ilium (83%)	Lymphangitic (75%)
Skin of the deep pelvic lymph nodes (5%)	Ischium (78%)	Solid/nodular (25%)
Bilateral involvement (57%)	Lumbosacral spine (71%)	Microscopic only (50%)
	Thoracic spine (60%)	
	Ribs (53%)	
	Femur (48%)	
	Shoulder (39%)	

\*Data from McLaughlin et al.<sup>9</sup>

†Data from Byar.<sup>10</sup>

‡Data from Varkarakis et al.<sup>11</sup>

**Table 3.** Published Reports of Uncommon PAC Manifestations Involving Skip Lymphadenopathy

Source	Findings
	<b>Supraclavicular lymph node involvement</b>
Butler et al <sup>12</sup>	Left side: 18/19 Right side: 1/19
Saeter et al <sup>13</sup>	Left side: most common nonregional lymphatic spread
	<b>Superior vena cava obstruction</b>
McGarry <sup>14</sup>	Lymph node compression: 1 case
	<b>Airway compression</b>
Cozzi and Schmidt <sup>15</sup>	Lymph node compression: 1 case

PAC = prostatic adenocarcinoma.

disease in patients with malignant ascites treated with peritoneovenous shunts all highlight the central role played by microenvironment factors.<sup>22</sup> In the same vein, the growth milieu of carcinoma cells may be a critical factor; the first case presented indicates that some clones of PAC cells are best suited to grow in the milieu of lymphatic drainage of the porta hepatis.

**SUMMARY**

The preceding article has described 2 cases of advanced PAC with unusual clinical presentations (eg, the compression of vital organs because of massive metastatic nodal disease and the sparing of the skeletal system and pelvic lymph nodes). In both cases, evaluation of the PSA tumor marker led to the proper working

**Table 4.** Published Cases of PAC Initially Presenting as Obstructive Jaundice

Source	Findings
Bloch and Block <sup>17</sup>	Carcinomatous involvement of common bile duct
Reddy et al <sup>18</sup>	Intermittent intrahepatic cholestasis
Cole et al <sup>19</sup>	Retroperitoneal, peripancreatic, and periaortic lymphadenopathy

PAC = prostatic adenocarcinoma.

diagnosis, which was confirmed by the dramatic response to androgen depletion. We were not able to discern in these 2 cases any morphologic differences from standard cases of PAC that would account for their unusual metastatic behavior, leading to the conclusion that the difference must lie at the molecular level. **HP**

**ACKNOWLEDGMENT**

The authors wish to thank Paula Green for her help in the literature search.

**REFERENCES**

1. Oh WK, Hurwitz M, D’Amico AV, Richie JP. Prostatic neoplasms. In: Bast RC, Gansler TS, Holland JF, Frei E, editors. Cancer medicine. 5th ed. New York: BC Decker; 2000:1559–88.
2. Oesterling JE, Fuks Z, Lee CT, Scher HI. Cancer of the prostate. In: DeVita VT Jr, Hellman S, Rosenberg SA, editors. Cancer: principles and practice of oncology. 5th ed. Philadelphia: Lippincott-Raven; 1997:1322–76.
3. Greenlee RT, Hill-Harmon MB, Murray T, Thun M. Cancer statistics, 2001 [published erratum appears in

- CA Cancer J Clin 2001;51:144]. CA Cancer J Clin 2001;51:15–36.
4. Garnick MB. Prostate cancer: screening, diagnosis, and management [published erratum appears in Ann Intern Med 1994;120:698]. Ann Intern Med 1993;118:804–18.
  5. Yu KK, Hawkins RA. The prostate: diagnostic evaluation of metastatic disease. Radiol Clin North Am 2000; 38:139–57.
  6. Elkin M, Mueller HP. Metastases from cancer of the prostate: autopsy and roentgenological findings. Cancer 1954;7:1246–8.
  7. Jacobs SC. Spread of prostatic cancer to bone. Urology 1983;21:337–44.
  8. Saitoh H, Hida M, Shimbo T, et al. Metastatic patterns of prostatic cancer. Correlation between sites and number of organs involved. Cancer 1984;54:3078–84.
  9. McLaughlin AP, Saltzstein SL, McCullough DL, Gittes RF. Prostatic carcinoma: incidence and location of unsuspected lymphatic metastases. J Urol 1976;115:89–94.
  10. Byar DP. VACURG studies on prostate cancer and its treatment. In: Tannenbaum M, editor. Urologic pathology: the prostate. Philadelphia: Lea & Febiger; 1977.
  11. Varkarakis MJ, Winterberger AR, Gaeta J, et al. Lung metastases in prostatic carcinoma. Urology 1974;3:447–52.
  12. Butler JJ, Howe CD, Johnson DE. Enlargement of the supraclavicular lymph nodes as the initial sign of prostatic carcinoma. Cancer 1971;27:1055–63.
  13. Saeter G, Fossa SD, Ous S, et al. Carcinoma of the prostate with soft tissue or non-regional lymphatic metastases at the time of diagnosis: a review of 47 cases. Br J Urol 1984; 56:385–90.
  14. McGarry RC. Superior vena cava obstruction due to prostate carcinoma. Urology 2000;55:436.
  15. Cozzi PJ, Schmidt GA. Airway compression by a mediastinal mass. Chest 1994;106:1237–8.
  16. Coakley JF, Ranson DL. Metastases to the larynx from a prostatic carcinoma. A case report. J Laryngol Otol 1984;98:839–42.
  17. Bloch WE, Block NL. Metastatic prostate cancer presenting as obstructive jaundice. Urology 1992;40:456–7.
  18. Reddy AN, Grosberg SJ, Wapnick S. Intermittent cholestatic jaundice and nonmetastatic prostate carcinoma. Arch Int Med 1977;137:1616–8.
  19. Cole A, Mendelblatt D, Aguayo J, et al. Metastatic prostate cancer (with prostate-specific antigen of 9996) presenting as obstructive jaundice. Am J Med Sci 2000;319:118–22.
  20. Matsumura Y, Tarin D. Significance of CD44 gene products for cancer diagnosis and disease evaluation. Lancet 1992;340:1053–8.
  21. Flanigan RL, Shankay TV. The natural history of human prostate cancer. In: Raghavan D, Scher HI, Leibel SA, Lange PH, editors. Principles and practice of genitourinary oncology. Philadelphia: Lippincott-Raven; 1997: 443–550.
  22. Tarin D, Price JE, Kettlewell MG, et al. Clinicopathological observations on metastasis in man studied in patients treated with peritoneovenous shunts. Br Med J (Clin Res Ed) 1984;288:749–51.

Copyright 2002 by Turner White Communications Inc., Wayne, PA. All rights reserved.