

Chylous Ascites Caused by Sarcoidosis

Grace Z. Mak, MD

Jenifer H. Welsh, MD

Elmer Chang, MD, CM

Ruth B. Lathi, MD

E. Lee Poythress, MD

Chylous ascites normally results from a rupture of the thoracic duct or from lymphatic obstruction.¹⁻⁴ Lymphatic involvement by sarcoid granulomas causes obstruction of the lymphatic system, leading to extravasation of lymph into the peritoneal cavity.^{5,6} This article presents the case of a 67-year-old black woman with a history suggestive of sarcoidosis who developed chylous ascites.

CASE PRESENTATION

Patient Presentation and History

A postmenopausal 67-year-old black woman came to the emergency department because of a 2-month history of increasing abdominal girth, decreased appetite, early satiety, and a weight loss of approximately 50 pounds over the past year. During the previous 2 days, she had developed lower extremity edema. She also reported a 2-month history of a nonproductive cough unrelieved by cough syrup with codeine. She reported no fever, chills, night sweats, nausea, vomiting, diarrhea, pelvic or abdominal pain, vaginal bleeding, melena, or changes in bowel or bladder habits.

The patient's medical history included hypertension, arthritis, glaucoma, and syphilis diagnosed 7 years previously. She had a persistently elevated rapid plasma reagin (RPR) level caused by prior use of methyldopa.

Six years previously, the patient had been diagnosed with bilateral anterior uveitis, which was most likely caused by syphilis. However, the diagnosis of sarcoidosis had also been considered. At that time, she had negative results on a purified protein derivative (tuberculin) skin test and no abnormalities on chest radiography; angiotensin-converting enzyme (ACE) and vitamin D levels had been within normal limits.

Two years previously, the patient had been re-evaluated because of abnormal results on chest radiography. Physical examination at that time had revealed

a left supraclavicular lymph node. A computed tomography (CT) scan of the chest had shown bilateral hilar adenopathy. The patient's ACE level had been 85 U/L (normal, 8-52 U/L); results on pulmonary function testing (PFT) had been normal. Fine-needle aspiration of the supraclavicular lymph node had revealed histiocytes and rod-shaped organisms staining positive for acid-fast bacilli (AFB). Lymph node cultures and sputum stains and cultures had all been negative for any organisms. The patient had received empirical treatment for scrofula for 6 months. Her supraclavicular lymph node had resolved, but her chest radiograph had remained abnormal. The patient had been followed in the pulmonary clinic ever since that time with a diagnosis of interstitial lung disease.

Two months previously, the patient had reported a dry, nonproductive cough and increasing abdominal girth. Follow-up PFTs had revealed a new mild restrictive pattern with decreased diffusing capacity. An upper gastrointestinal barium study had revealed extrinsic compression of the stomach.

The patient was admitted to the hospital for evaluation. Her medications at admission included ibuprofen, albuterol inhaler, cetirizine, pseudoephedrine, docusate sodium ear drops, and dorzolamide eye drops. She had smoked 2 packs of cigarettes daily for 40 years, quitting 17 years ago, and drank alcohol heavily in the distant past.

Dr. Mak is a Resident in General Surgery, University of Cincinnati, Cincinnati, OH. Dr. Welsh is a Flight Surgeon, United States Air Force Academy, Colorado Springs, CO. Dr. Chang is an Internist, The Permanente Medical Group, Inc., Union City, CA. Dr. Lathi is a Fellow in Reproductive Endocrinology and Infertility, Department of Obstetrics and Gynecology, Stanford University School of Medicine, Stanford, CA. Dr. Poythress is an Assistant Professor of Medicine, Department of Medicine, Baylor College of Medicine, Houston, TX.

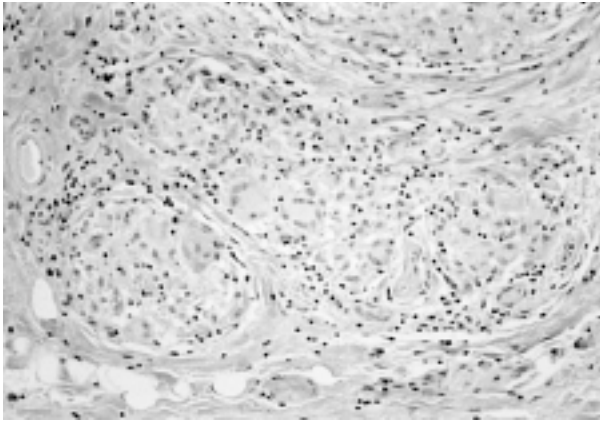


Figure 1. Photomicrograph of a peritoneal biopsy specimen from the case patient showing nonnecrotizing granulomas. Similar granulomas were also found in a specimen from the lung transbronchial biopsy (hematoxylin-eosin, original magnification $\times 200$).

Physical Examination and Chest Radiography

Physical examination revealed a blood pressure of 151/88 mm Hg, scattered crackles in bilateral lung fields, a distended abdomen with tense ascites, and pitting edema of the lower extremities. A chest radiograph revealed fibrous interstitial changes and enlarged hila bilaterally.

Laboratory Measurements

Initial serum levels of electrolytes, urea nitrogen, creatinine, calcium, bilirubin (total and direct), alkaline phosphatase, aspartate aminotransferase, and alanine aminotransferase were all within normal limits. Total serum protein level was 7.2 g/dL (normal, 6.0–8.0 g/dL), and serum albumin level was 2.9 g/dL (normal, 3.5–5.0 g/dL). The corrected calcium, hemoglobin, hematocrit, and platelet levels were also within normal limits. The leukocyte count was low at $3.1 \times 10^3/\text{mm}^3$ (normal, $4.5\text{--}12.0 \times 10^3/\text{mm}^3$), with 61% polymorphonuclear cells, 22% lymphocytes, 11% monocytes, 5% eosinophils, and 1% basophils. Prothrombin time and partial thromboplastin time were normal. The RPR was reactive at 1:256.

Peritoneal Fluid Analysis

Analysis of the peritoneal fluid was significant for grossly milky fluid with a glucose level of 93 mg/dL, total protein level of 6 g/dL, triglyceride level of 1260 mg/dL, lactate dehydrogenase level of 127 U/L, amylase level of 90 U/L, and serum-to-ascites albumin gradient of 0.9 g/dL. The peritoneal fluid leukocyte

count was $2 \times 10^3/\text{mm}^3$, with 1% polymorphonuclear cells, 77% lymphocytes, and 20% macrophages. Results of a routine Gram stain and culture, an anaerobic culture, a fungal stain and culture, an AFB stain and culture, and polymerase chain reaction for *Mycobacterium tuberculosis* were all negative. The cytology and flow cytometry of the peritoneal fluid were both negative for malignancies.

Additional Studies

Subsequent laboratory measurements revealed an ACE level of 204 U/L. A microhemagglutination-*Treponema pallidum* test showed a positive result. CT scans of the chest, abdomen, and pelvis revealed hilar adenopathy, pulmonary changes showing atelectasis or fibrosis, periaortic and retroperitoneal lymphadenopathy, a normal liver, and uterine fibroids. A transvaginal ultrasound confirmed the presence of uterine fibroids. Results of a Papanicolaou test were within normal limits. Serum markers for α -fetoprotein, carcinoembryonic antigen, and carbohydrate antigen 19-9 were negative, as was an HIV-1 enzyme immunoassay. Cancer antigen 125 (CA-125) level was elevated at 144 U/mL (normal, < 35 U/mL).

Evaluation for possible sarcoidosis prompted a bronchoscopy, which showed a cobblestone appearance of the bronchial wall with plaques throughout the bronchial tree. Transbronchial biopsy revealed noncaseating granulomas; stains and cultures were negative for AFB. A brush biopsy specimen of a plaque also was negative for AFB on stain and culture. Bronchial washings were negative for malignancy.

Management

The patient was referred to the gynecology service for continued evaluation of the chylous ascites in the presence of an elevated CA-125 level and large uterine fibroids. Gynecologic evaluation revealed a large, fixed, firm pelvic mass approximately 10 cm in diameter. An exploratory laparotomy for tissue diagnosis was performed, and 1700 mL of chylous ascites was drained and sent for laboratory culture. Biopsy was performed on multiple small 2- to 5-mm tannish-pink nodules on the peritoneal and serosal surfaces. Frozen sections of the peritoneum revealed multiple granulomas without evidence of malignancy. Based on these findings, active abdominal tuberculosis could not be ruled out, and the patient began a 5-drug treatment regimen for tuberculosis. Final pathology of the peritoneal biopsy specimens and ascites fluid showed noncaseating granulomas with negative results on AFB and fungal stains (**Figure 1**).

Outcome

On follow-up evaluation approximately 6 weeks after the patient's discharge from the hospital, all AFB and fungal stains and cultures showed negative results, and the antituberculous medications were discontinued. Repeat physical examination was remarkable for resolution of ascites. Repeat laboratory evaluation yielded an ACE level of 94 U/L. PFTs showed no significant change, and CA-125 remained elevated.

Six months later, PFTs showed marked improvement, with normal results on spirometry. The patient, however, continued to complain of a chronic cough. Repeat bronchoscopy showed no endobronchial lesions, which were visible 11 months earlier. The patient received treatment for gastroesophageal reflux disease, and her cough improved.

DISCUSSION

General Considerations

Ascites is an uncommon manifestation of sarcoidosis. Although it has most often been associated with portal hypertension secondary to hepatic involvement,^{7–10} it may less commonly be the primary manifestation of peritoneal sarcoidosis or lymphatic obstruction.^{5,6,10–23}

Review of Literature

Using a MEDLINE search with the key words "ascites" and "sarcoidosis" and the subsequent bibliographies from those sources, we identified 13 well-documented English literature cases of ascites caused by either sarcoidosis of the peritoneum or lymphatic obstruction (Table 1).^{5,6,10–18,20} Using all languages and the same search methods, we identified a total of 18 documented cases of peritoneal sarcoidosis.^{10–18,21,24–29} Eleven of those cases were associated with ascites.^{10–18,21} We identified only 4 cases of ascites associated with lymphatic obstruction.^{5,6,20,22} Cases of chylous ascites secondary to surgical manipulation of either the thoracic duct or the inferior vena cava were not considered primary manifestations of sarcoidosis and thus were not included in these numbers.^{1,2} Two other cases were noted to have probable associations between ascites and peritoneal sarcoidosis.^{19,23} This case report is the third documented case of chylous ascites caused by sarcoidosis and the third documented case of an elevated CA-125 level caused by sarcoidosis.

Etiology and Pathogenesis

The term *chylous ascites* describes the peritoneal fluid's milky appearance caused by the presence of lymph, which is primarily composed of chylomicrons. The fluid characteristically has a triglyceride level

greater than 1000 mg/dL and the histologic appearance of Sudan-staining fat globules.³⁰ Normally, chylous ascites results from the rupture of the thoracic duct or from lymphatic obstruction.^{1–4} Most reported cases (87%) of chylous ascites in adults are caused by malignancy.² In infants and children, chylous ascites is usually secondary to congenital malformations or inadvertent surgical ligation of the thoracic duct.² The most likely pathogenesis for the chylous ascites in sarcoidosis is either (1) extrinsic obstruction of the thoracic duct secondary to intra-abdominal lymphadenopathy or (2) intrinsic lymph node obstruction caused by node infiltration by granulomas or fibrosis.^{5,6}

The natural course of sarcoidosis varies according to the level of involvement of the lungs and other organ systems. Despite general guidelines,³¹ the best approach to prognosis is performing serial clinical examinations of the patient with determination of the severity of organ involvement.³² Case reports of sarcoid-induced ascites describe a clinically benign course (Table 1).^{5,6,10–18,20}

Diagnosis

The case patient's clinical presentation and laboratory and radiographic findings are consistent with the diagnosis of sarcoidosis. This patient did have an elevated CA-125 level, which is present in a number of benign and malignant conditions involving the peritoneal cavity.^{20,26,33–38} The patient's elevated CA-125 level was likely secondary to diffuse studding of her peritoneum with granulomas. Only 2 other cases of peritoneal sarcoidosis with an elevated CA-125 level have been reported, 1 with ascites.^{20,26}

Treatment

Treatment of sarcoid-induced ascites has varied. Of the reported cases, 5 patients have received steroid therapy alone,^{5,11,15,16,18} 3 patients have received antituberculous therapy alone,^{10,13,14} and 1 patient received both therapies.¹⁴ Most cases resolved within a few weeks to months, regardless of treatment. The recognition of peritoneal or lymphatic sarcoidosis-induced ascites as a benign entity is well reported in the literature.^{10,11,14}

Patient Follow-up

Currently, the case patient has experienced resolution of her ascites and has minimal pulmonary manifestations of her sarcoidosis on PFTs. Corticosteroid therapy has not been initiated. She will be followed by the internal medicine, pulmonary medicine, and gynecology services and will be monitored with CA-125 measurements, pelvic ultrasound examinations at 3-month

Table 1. Reported Cases of Sarcoidosis with Ascites in the English Literature

Study	Sex, Race, Age (y)	Type of Ascites Fluid	TB Culture	Cytology*	Peritoneal Findings [†]	Laparotomy Findings	Treatment/Follow-up
Mak et al	F, B, 67	Chylous	– (PCR and culture)	–	+	Diffuse 2–5-mm tannish-pink nodules; dense adhesions	No treatment; no recurrence after 9 mo
Provenza et al ⁵	F, B, 33	Chylous	–	–	+	Diffusely matted mesentery and retroperitoneal lymph nodes	Frequent large-volume paracenteses, prednisone and low fat, MCTG diet for 5 mo; no recurrence 2 mo after steroid tapered
Cappell et al ⁶	F, B, 51	Chylous	–	–	+	(7 y prior) No laparotomy performed	Dietary fluid and salt retention; death 3 mo later from respiratory failure; chylous ascites found at autopsy and fibrotic mediastinal LAD without granulomas
Papowitz et al ¹⁰	F, B, 28	Serous	–	– (frozen sections at surgery)	+	Enlarged spleen; diffuse small white nodules on omentum, mesentery, pancreas, and spleen	Anti-TB therapy for 1 y; no other treatment; no recurrence at 2.5 y
Wong et al ¹¹	M, NA, 24	Clear, yellow	–	–	+	Diffuse hard white nodules over the peritoneum and serosa; mesenteric LAD	Sodium restriction and diuretic; recurrence 1 y later; unresponsive to diuretics and sodium restriction requiring maintenance prednisone with no other reported recurrences
Becker et al ¹²	F, B, 39	Turbid, yellow	NA	NA	+	Enlarged spleen and liver; diffuse small gray-white nodules on omentum, peritoneum, and organs	No treatment; death 4 y later from cor pulmonale with no ascites at autopsy
Arena ¹³	F, W, 53	Serous	–	–	+	Liver studded with white patches; (on follow-up laparotomy, peritoneum covered with white patches)	Anti-TB therapy; no other treatment; no recurrence at 2 y

(continued on next page)

Table 1. (continued) Reported Cases of Sarcoidosis with Ascites in the English Literature

Study	Sex, Race, Age (y)	Type of Ascites Fluid	TB Culture	Cytology*	Peritoneal Findings†	Laparotomy Findings	Treatment/Follow-up
Wheeler et al ¹⁴	F, B, 29	Bloody	-	NA	NA (+ on cervical lymph node biopsy)	Liver and enlarged spleen studied with yellow lesions	Anti-TB therapy for 1 y; prednisone for 4 mo and taper; no recurrent ascites at 10 y
Wheeler et al ¹⁴	F, B, 42	Bloody	-	NA	+	Diffuse 1-mm white nodules covering entire abdominal cavity	Anti-TB therapy until cultures negative; persistent ascites for 8 y; no other treatment; no ascites reported over subsequent 2 y with abdominal surgery revealing persistent peritoneal noncaseating granulomas and negative cultures
Robertson et al ¹⁵	M, B, 14	Bloody	NA (- stain and PPD)	NA	+	No laparotomy performed; peritoneoscopy with diffuse 1-2-mm white nodules on visceral and parietal peritoneum	Prednisone for 6 wk then taper; no recurrence at 6 mo
Ngo et al ¹⁶	F, W, 53	Bloody	-	NA	No granulomas found	Ascites; ovarian cystadenofibromas, and sclerosing peritonitis	Corticosteroid taper to 15 mg daily with complete resolution of symptoms; no recurrence at 6 mo
Uthman et al ¹⁷	F, Asian, 32	Not reported	-	NA	+	Hard mass at surgical site, hard white nodules on peritoneum, and ascites	No treatment; 6-mo follow-up CT showed edema at laparotomy site and no change in some chest nodes
Santolaria-Fernandez et al ¹⁸	M, NA, 57	Exudative	NA (PPD -)	NA	+	Peritoneum covered with whitish nodules	Prednisone; resolved ascites; no recurrence at 30 mo
Edmond et al ²⁰	F, B, 38	Bloody	NA (PPD -)	-	NA (+ on liver biopsy)	Not reported (LAD and ascites on CT scan)	Not reported

- = negative; + = positive; Abd = abdominal; B = black; CT = computed tomography; F = female; LAD = lymphadenopathy; M = male; MCTG = medium chain triglycerides; NA = not available; PCR = polymerase chain reaction; PPD = purified protein derivative (tuberculin) test; TB = tuberculosis; W = white.

*Cytology for malignancy.

†Peritoneal findings of noncaseating granulomas.

Adapted from Wheeler JE, Rosenthal NS. Bloody ascites in sarcoidosis. Chest 1985;88:917-8.

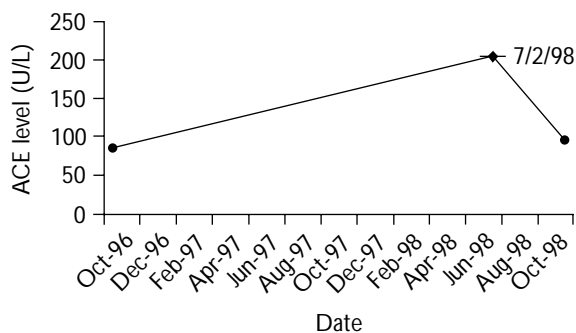


Figure 2. Progression of angiotensin-converting enzyme levels in the case patient over a 2-year period. Peak level was 204 U/L on July 2, 1998, at the time of diagnosis. The follow-up level of 94 U/L correlates with the spontaneous regression of symptoms.

intervals, PFTs, and evaluation of her ACE levels. Her latest CA-125 level has remained stable, and her current ACE level is 94 U/L, which is consistent with spontaneous regression of sarcoidosis (Figure 2).

CONCLUSION

This article reports a case of sarcoidosis presenting as chylous ascites with an elevated CA-125 level in a woman who subsequently had spontaneous regression of her disease. Evaluations for other neoplastic and infectious abdominal processes proved negative. This is only the third reported case in the English literature of sarcoidosis presenting with either chylous ascites or an abnormal CA-125 level. **HP**

REFERENCES

- Sontag S, Chejfec G, Stanley M, Nemchausky B. Post-surgical chylous ascites in sarcoidosis with portal hypertension. *J Clin Gastroenterol* 1985;7:327-30.
- Press OW, Press NO, Kaufman SD. Evaluation and management of chylous ascites. *Ann Intern Med* 1982;96:358-64.
- Kelley ML, Butt HR. Chylous ascites: an analysis of its etiology. *Gastroenterology* 1960;39:161-70.
- Rector WG Jr. Spontaneous chylous ascites of cirrhosis. *J Clin Gastroenterol* 1984;6:369-72.
- Provenza JM, Bacon BR. Chylous ascites due to sarcoidosis. *Am J Gastroenterol* 1991;86:92-5.
- Cappell MS, Friedman D, Mikhail N. Chyloperitoneum associated with chronic severe sarcoidosis. *Am J Gastroenterol* 1993;88:99-101.
- Valla D, Pessegueiro-Miranda H, Degott C, et al. Hepatic sarcoidosis with portal hypertension. A report of seven cases with a review of the literature. *Q J Med* 1987;63:531-44.
- Tekeste H, Latour F, Levitt RE. Portal hypertension complicating sarcoid liver disease: case report and review of the literature. *Am J Gastroenterol* 1984;79:389-96.
- Longcope WT, Frieman DG. A study of sarcoidosis. *Medicine* 1952;31:1-128.
- Papowitz AJ, Li JK. Abdominal sarcoidosis with ascites. *Chest* 1971;59:692-5.
- Wong M, Rosen SW. Ascites in sarcoidosis due to peritoneal involvement. *Ann Intern Med* 1962;57:277-80.
- Becker WF, Coleman WO. Surgical significance of abdominal sarcoidosis. *Ann Surg* 1961;153:987-95.
- Arena FP. Clinicopathology conference. A patient with ascites and hypercalcemia. *Clin Bull* 1979;9:117-25.
- Wheeler JE, Rosenthal NS. Bloody ascites in sarcoidosis. *Chest* 1985;88:917-8.
- Robertson LE Jr, Cunningham JT. Primary peritoneal sarcoidosis. *Dig Dis Sci* 1990;35:1545-8.
- Ngo Y, Messing B, Marteau P, et al. Peritoneal sarcoidosis. An unrecognized cause of sclerosing peritonitis. *Dig Dis Sci* 1992;37:1776-80.
- Uthman IW, Bizri AR, Shabb NS, et al. Peritoneal sarcoidosis: case report and review of the literature. *Semin Arthritis Rheum* 1999;28:351-4.
- Santolaria-Fernandez F, Hernandez-Marrero D, Gonzalez-Reimers E, Batista-Lopez N. Peritoneal sarcoidosis [letter]. *Arch Intern Med* 1988;148:233, 237.
- Reisner D. Boeck's sarcoid and systemic sarcoidosis. *Am Rev of Tuberculosis* 1944;49:451.
- Edmond M, Borrelli GS, Wenzel RP. Case records of the Medical College of Virginia, Virginia Commonwealth University, clinicopathologic conference. Case presentation. A 38-year-old woman with new-onset ascites. *Am J Med Sci* 1997;313:170-5.
- Santolaria Fernandez F, Gonzalez Reimers E, Jorge Hernandez JA, et al. [Peritoneal sarcoidosis.] [Article in Spanish.] *Rev Clin Esp* 1981;160:63-4.
- Lohkamp F, Hiness R. [Extra-thoracic sarcoidosis of the retroperitoneal lymph nodes and of the spleen with ascites. Comment on the problem of lymphatic obstruction (author's transl).] [Article in German.] *ROFO Fortschr Geb Rontgenstr Nuklearmed* 1976;125:358-61.
- Takahashi N, Enomoto T, Hagiwara T, et al. [A case of sarcoidosis presenting with Heerfordt's syndrome, associated with hepatosplenomegaly, pleural effusion, and ascites.] [Article in Japanese.] *Nihon Kyobu Shikkan Gakkai Zasshi* 1992;30:684-8.
- Montamus WP. Boeck's sarcoid. *J Med* 1938;19:76-8.
- Robinson EK, Ernst RW. Boeck's sarcoid of the peritoneal cavity. *Surgery* 1954;36:986-91.
- Trimble EL, Saigo PE, Freeberg GW, et al. Peritoneal sarcoidosis and elevated CA 125. *Obstet Gynecol* 1991;78(5 Pt 2):976-7.
- Thomas J, Williams DW. Peritoneal involvement and ulcerative skin plaques in sarcoidosis: a case report. *Sarcoidosis* 1989;6:161-2.
- Michard P, Marin I, Tirouvanziam JM, et al. [Peritoneal sarcoidosis, a rare localization.] [Article in French.]

(continued on page 36)

(from page 32)

- Presse Med 1987;16:959-62.
29. Leleu O, Aron C, Lavallard B, et al. [Surgical emergency disclosing sarcoidosis. Apropos of a case.] [Article in French.] *Rev Pneumol Clin* 1996;52:196-8.
 30. Glickman RM, Isselbacher KJ. Abdominal swelling and ascites. In: Fauci AS, Braunwald E, Isselbacher KJ, et al., editors. *Harrison's principles of internal medicine*. 14th ed. New York: McGraw-Hill; 1998:255-7.
 31. Consensus conference: activity of sarcoidosis. Third WASOG meeting, Los Angeles, USA, September 8-11, 1993. *Eur Respir J* 1994;7:624-7.
 32. Newman LS, Rose CS, Maier LA. Sarcoidosis [published erratum appears in *N Engl J Med* 1997;337:139]. *N Engl J Med* 1997;336:1224-34.
 33. Eddy GL Sr. Pelvic hematoma following angiography: another cause of elevated serum CA-125. *Gynecol Oncol* 1997;65:370-2.
 34. McBean JH, Brumsted JR. In vitro CA-125 secretion by endometrium from women with advanced endometriosis. *Fertil Steril* 1993;59:89-92.
 35. Gurgan T, Zeyneloglu H, Urman B, et al. Pelvic-peritoneal tuberculosis with elevated serum and peritoneal fluid CA-125 levels. A report of two cases. *Gynecol Obstet Invest* 1993;35:60-1.
 36. Halila H, Stenman UH, Seppala M. Ovarian cancer antigen CA 125 levels in pelvic inflammatory disease and pregnancy. *Cancer* 1986;57:1327-9.
 37. Bergmann JF, Bidart JM, George M, et al. Elevation of CA 125 in patients with benign and malignant ascites. *Cancer* 1987;59:213-7.
 38. Talbot RW, Jacobsen DJ, Nagorney DM, et al. Temporary elevation of CA 125 after abdominal surgical treatment for benign disease and cancer. *Surg Gynecol Obstet* 1989;168:407-12.

Copyright 2002 by Turner White Communications Inc., Wayne, PA. All rights reserved.